

RESEARCH ARTICLE

The Effect of Honey in Second Degree Burn Healing on Wistar Rats (Overview of Angiogenesis and the Number of Fibroblasts)

Ayyasi Izaz Almas¹, Ratna Dama Purnawati², Hermawan Istiadi³, Neni Susilaningsih^{2*}

¹ The student of Medicine Faculty, Diponegoro University, Semarang, Indonesia

² Histology Department, Faculty of Medicine, Diponegoro University, Semarang, Indonesia

³ Pathology Department, Faculty of Medicine, Diponegoro University, Semarang, Indonesia

*corresponding author, email: nenisus2002@yahoo.com

ABSTRACT

Introduction: Burn therapy is generally done using a burn ointment. However, honey can also be used as an alternative treatment for burns. Honey contains active flavonoid as an antioxidant and hydrogen peroxide which can stimulate fibroblasts proliferation also angiogenesis on burn healing phase.

Objective: to determine the effect of honey in second degree burn healing from angiogenesis and the number of fibroblasts on Wistar rats.

Methods: This research used a posttest only controlled group design on 15 rats with random selection and divided into 3 groups: H-G was given honey, B-G was given Bioplacenton®, N-G without any treatment after burn was induced. Rats were given a second degree burn in a size of 2 cm x 2cm on the back area and were treated twice a day for 14 days. Burn healing was measured by calculating the observation results of microscopic VEGF expression, the number of neovascularization, and the number of fibroblasts. Hypothesis analysis used Annova post hoc LSD and Mann-Whitney.

Results: The highest mean in VEGF expression and the number of neovascularization was obtained from group B-G followed by group H-G and group N-G. Significant differences in the number of neovascularization between group B-G with group N-G, $p < 0.05$.

Conclusion: Honey can provide a healing effect on the second degree of burns in Wistar rats in terms of the number of neovascularization as well as Bioplacenton®.

Keywords: honey, flavonoid, antioxidant, angiogenesis

ABSTRAK

Pendahuluan: Terapi luka bakar umumnya dilakukan dengan menggunakan salep luka bakar. Namun, madu juga dapat digunakan sebagai alternatif pengobatan luka bakar. Madu memiliki kandungan aktif flavonoid yang berperan sebagai antioksidan dan hidrogen peroksida yang dapat merangsang proliferasi fibroblas serta angiogenesis dalam fase penyembuhan luka bakar. **Tujuan:** mengetahui pengaruh madu dalam penyembuhan luka bakar derajat II ditinjau dari angiogenesis dan jumlah fibroblas pada tikus Wistar.

Metode: Penelitian ini menggunakan rancangan *post test only controlled group design* terhadap 15 tikus yang dipilih secara random, dibagi menjadi 3 kelompok yaitu H-G diberi olesan madu, B-G diberi olesan Bioplacenton®, dan N-G tanpa perlakuan setelah diinduksi luka bakar. Tikus diberi luka bakar derajat II dengan ukuran 2cmx2cm di daerah punggung dan diberikan perawatan 2 kali sehari selama 14 hari. Penyembuhan luka bakar diukur dengan menghitung hasil pengamatan mikroskopis ekspresi VEGF, neovaskularisasi, dan jumlah fibroblas. Analisis hipotesis dilakukan dengan uji *Annova Post Hoc LSD* dan *Mann-Whitney*.

Hasil: Rerata ekspresi VEGF dan jumlah neovaskularisasi paling tinggi didapatkan pada kelompok B-G diikuti kelompok H-G dan kelompok N-G. Perbedaan signifikan pada variabel jumlah neovaskularisasi antara kelompok B-G dengan N-G, $p < 0.05$.

Kesimpulan: Madu dapat mempengaruhi proses penyembuhan luka bakar derajat II pada tikus Wistar ditinjau dari jumlah neovaskularisasi seperti halnya dengan Bioplacenton®.

Kata Kunci: madu, flavonoid, antioksidan, angiogenesis

INTRODUCTION

World Health Organization (WHO) states that the number of deaths caused by burns in the world each year are about 300,000 (WHO, 2014). Meanwhile in Indonesia, the death rate from burns is still high around 40% (Wardhana, A. et al., 2017). The main causes of the high death toll is severe degree burns. The result of National Basic Health Research (RISKESDAS) revealed that burns was ranked 6th in unintentional

injury with a total of 0.7% of all injuries (Wardhana, A. et al., 2017).

Second degree burns or partial-thickness burn is one of the most frequent occurrence in the household environment and require adequate treatment to prevent complications (Mobayyen, M. et al., 2017). Second degree burns are divided into IIA degree burns (partial thickness superficial) and IIB (deep partial thickness). Second degree burns require healing time

Copyright © 2020 Authors. This is an open access article distributed under the terms of the Creative Commons Attribution-NonCommercial-ShareAlike 4.0 International License (<http://creativecommons.org/licenses/by-nc-sa/4.0/>), which permits unrestricted non-commercial use, distribution, and reproduction in any medium, provided the original author and source are properly cited.

Almas, et al.

for two to three weeks through three stages phases of inflammation, proliferation, and remodeling (Barbara, A.B. et al., 2013).

Treatment of burns is very important to do because it can accelerate wound healing by providing the burn wound dressing or topical antimicrobial agent which can be obtained from natural materials bee therapy or apitherapy (Fromm, D., 2011). Bee therapy or apitherapy defined as a treatment that uses a wide range of bee products are: honey, bee pollen, bee bread, propolis, bee venom, royal jelly (Frans, J.B., 2013). The products most commonly used in the treatment of burns, namely honey because honey is antibacterial, antiseptic, anti-inflammatory, and antioxidant so it can accelerate the healing process of burns (Christy, E. et al., 2012). Pure honey contains about 40% glucose, 40% fructose, and 20% water. In addition, honey contains amino acids and vitamins include biotene, nicotinic acid, folic acid, pantothenic acid, pyridoxine, thiamine, and also enzymes such as diastase invertase, glutamine oxidase, catalase, and minerals in the form of potassium, iron, magnesium, phosphorus, copper, and calcium (Dai, T. et al., 2010).

The use of honey as a wound dressing helps create a moist environment so that debridement can be induced (Halim, D. et al., 2011). This happens due to the high osmotic pressure of the honey as well as the activation of protease induced by hydrogen peroxide. Aside from being antibacterial, honey acts as an antioxidant of flavonoid (quercetin) metabolites of compounds which can accelerate wound healing (Rao, P. et al., 2016).

Honey with its characteristics which tested clinically and histologically shows that its application on burns are able to accelerate the healing of burns and also useful as an effective antimicrobial agent. Based on these descriptions, the researchers were motivated to do further research on the effect of honey towards burn.

METHODS

This study uses a posttest only control group design with one treatment group and two control groups. Animal used in this study were white rats (*Rattus norvegicus*) Wistar male 2-3 months old, 150-200 g body weight, active movement, clean fur, clear sights, and had never received any previous treatment. Before the experiment, the experimental animals had been acclimatized for 7 days and placed in a separate enclosure for each sample in a closed room with a temperature of $\pm 22^\circ\text{C}$. Treatment began immediately after burning on day 8 to day 21, twice a day with a

span of giving 12 hours based on the group, namely H-G as a treatment of topical honey, B-G smeared Bioplacenton®, and N-G not applied any treatment after-induced burns. This study was approved by the Research Ethics Commission (KEPK) of the Faculty of Medicine, Diponegoro University/RSUP Dr. Kariadi Semarang for all animal experiments with number of ethical clearance 68/EC/H/KEPK/FK-UNDIP/V/2019.

Second-degree Burns of Skin

Burns given starting with determining the location of burns on the backs of rats and shaved about 2-3 cm. Disinfection was done with 70% alcohol on the part that will be given lesion to do anesthesia with 2% lidocaine infiltration in the skin of mice and waited for 2 minutes. After it is done making of burns on the backs of mice by using brass stamp of square-shaped iron plate 2cm x 2cm size are heated over the stove until it reaches a temperature of 120°C were measured with an infrared thermometer. Then the brass stamp affixed for 10 seconds on the backs of mice that have been given anesthesia to form the second-degree burns.

Skin Histopathologic Preparation

Skin sampling was performed on day 22 immediately after the rats were decapitated. Then the burns were made excision approximately 1-2 cm around it to create a block of paraffin for histopathologic preparation materials. Preparations were then given HE staining for microscopic observation of the number of neovascularization and the number of fibroblasts also immunohistochemically staining for microscopic observation of Vascular Endothelial Growth Factor (VEGF) expression.

Observation of the burn healing were observed from 3 parameters. The first parameter was the expression examination of VEGF observation under 400x magnification light microscopy on a 5 fields of view with calculations using immunoreactive score (IRS) method. The immunoreactive score (IRS) gives a range of 0-12 as a product of multiplication between positive cells proportion score (0-4) and staining intensity score (0-3). The percentage of postively stained cells was assigned as a numerical score: 0, negative; 1, <10%; 2, 11-50%; 3, 51-80%; and 4, > 80% postive cells. The intensity of the immunostained areas was defined as follows: 0, no color reaction; 1, mild reaction; 2, moderate reaction; 3, intense reaction. The final expression score was divided into 4 categories: 0-1= no expression; 2-3= weak expression; 4-8= moderate expression; 9-12= strong expression (Specht, E. et

al., 2015). The second parameter was observation of the mean number on neovascularization under 100x magnification light microscopy on a 5 fields of view.

The third parameter was observation of the mean number of fibroblasts under 400x magnification light microscopy on a 5 field of view.

Table 1. Mean of VEGF, Neovascularization, and Fibroblast Expression in Each group

Variables	Treatment Groups			P Values
	H-G	B-G	N-G	
	N=5. X(±SD)	N=5. X(±SD)	N=5. X(±SD)	
VEGF (%)	7.6 (±3.51)	8.6 (±2.88)	5.6 (±3.21)	0.315 [#]
Neovascularization (Σ)	32.8 (±15.31)	46.5 (±20.58)	16.1 (±11.13)	0.036 ^{##}
Fibroblasts (Σ)	68.6 (±7.89)	75.2 (±7.19)	72.2 (±7.46)	0.409 ^{##}

Note: #: Kruskal Wallis; ##: Anova

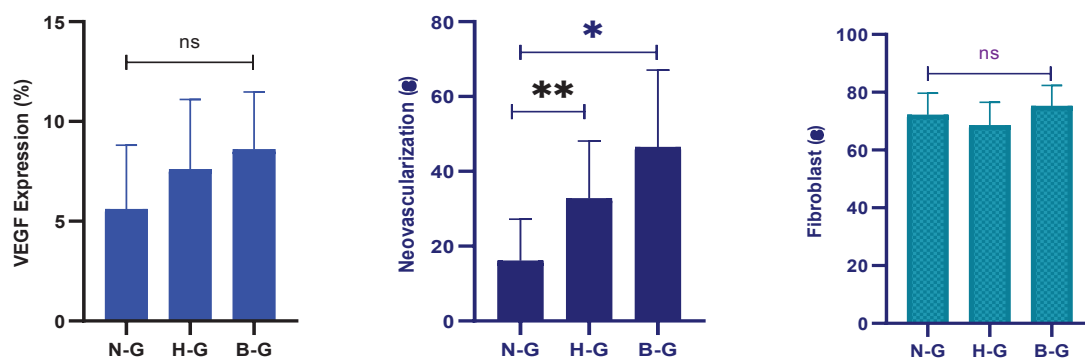


Figure 1. VEGF expression, number of neovascularization, and number of fibrosis in each group. Anova/ Kurskall Wallis analysis: ns: not significant; Post Hoc LSD analysis: * p<0.05; ** p>0.05

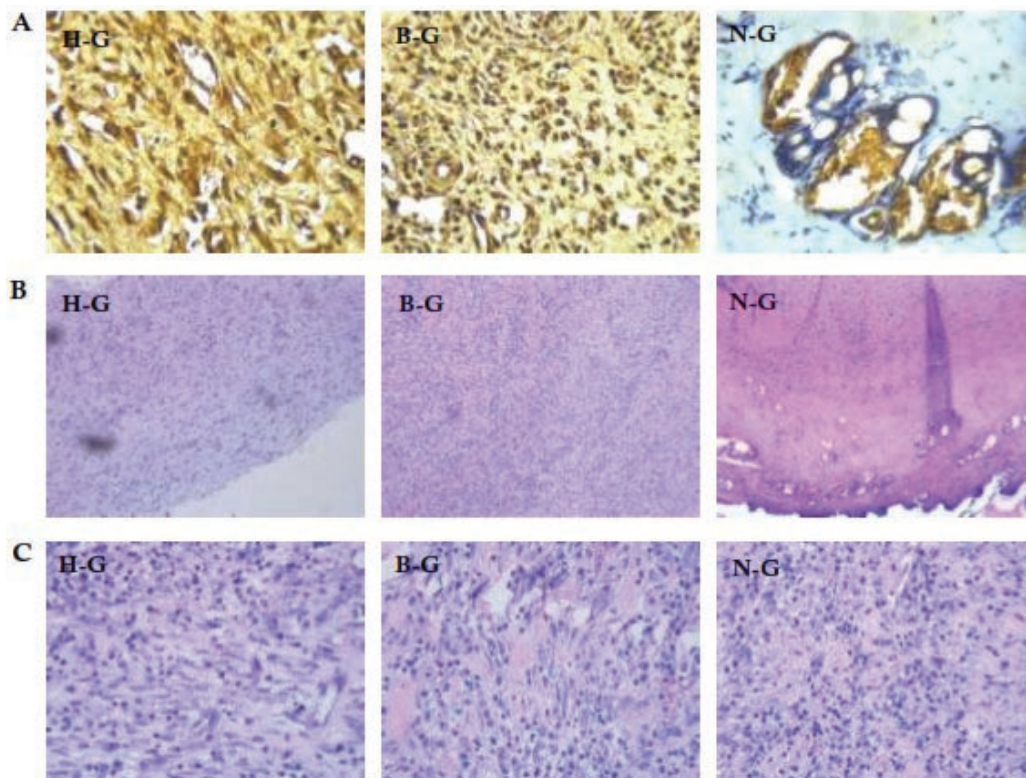


Figure 2. (A) VEGF expression with VEGF-A immunohistochemical staining (400x), (B) Neovascularization with HE staining (100x) and (C) Fibroblasts with HE staining (400x)

Almas, et al.

Statistical Analysis

Data analysis was performed by using a computer program and analyzed with Anova followed by Post Hoc LSD test. The significant level was considered if $p < 0.05$.

RESULTS

This research used VEGF expression as dependent variable, the number of neovascularization and the number of fibroblasts as an indicator of the ability pro-angiogenesis and pro-fibroblast from independent variables. Result of the measurement variables after treatment are summarized in table 1.

Based on the obtained data can be seen that the mean expression of VEGF and the number of neovascularization, Bioplacenton® as the highest in the group followed by honey and without treatment after burns induced. On the other hand, the highest mean number of fibroblasts remains on Bioplacenton® followed by no treatment and honey after induction of burns. Anova statistical analysis on number of neovascularizations show that there were significant difference amongst group, $p < 0.05$. In contrary, anova analysis on fibroblast expression, there were no significance different amongst groups, $p > 0.05$. Moreover, Kurskal Wallis analysis on VEGF expression show that there was no significant difference amongst group, $p > 0.05$. The result of the present study show that Bioplacenton® have the best mean from three microscopic observation those were VEGF expression (figure 2), the number of neovascularization, and the number of fibroblasts. Furthermore, considering only the number of neovascularization showed significantly different amongst groups in anova analysis, therefore merely the number of neovascularization to be tested in Post Hoc analysis to differentiate between two groups as described below.

Number of Neovascularization

Post Hoc LSD analysis indicate that number of neovascularization in honey group was not significant higher compared to that of Bioplacenton and negative groups, $p > 0.05$. In contrary, the number of neovascularization in Bioplacenton group was significant higher compared to that of negative group, $p < 0.05$ (figure 1).

Microscopic observations on VEGF expression preparations obtained from Bioplacenton® group and from honey groups were found endothelial cells and fibroblasts that were stained with strong stain intensity. Meanwhile, the microscopic observation on preparations the number of neovascularization and the

number of fibroblasts also known Bioplacenton® group there were many capillaries on the epidermis in form of lumen surrounded by a layer of endothelial cells and the number of oval-shaped cells which has had a nucleus in the center with a fine granular cytoplasm with extracellular matrix more than honey group and the untreated group.

DISCUSSIONS

Based on research it showed that the H-G group treated using smear honey on the burn area 2 times a day with 12 hours span for 14 days by microscopic observation of the expression of VEGF and the number of neovascularization got a higher mean than control group without treatment after burns induced. This shows that honey has the ability in burn healing process, because the active substance flavonoids and H₂O₂ (Kwakman, P.H.S. and Zaat, S.A.J., 2012).

One of flavonoid compounds in honey called quercetin (Rao, P. et al., 2016). Quercetin has the ability to counteract Reactive Oxygen Species (ROS). ROS has implications on the activation of the transcription factor NF- κ B which is sensitive to oxidative stress response (Fatmawati, H. et al., 2010). Activation of NF- κ B is a protein that can induce transcription of several genes that may stimulate inflammation by inducing the production of various inflammatory mediators, such as TNF- α . TNF- α is known to increase the expression of VEGF and its receptors that interleukin-8 and FGF2 on endothelial cells, so that the activity of TNF- α plays a role in angiogenesis in vivo (Vinay et al., 2012). Additionally, quercetin can stimulate the induction of vascular endothelial growth factor (VEGF) in the process of angiogenesis as it facilitates growth factors such as PDGF, EGF, TGF- β and FGF which play a role in the healing process of burns (Wang, N. et al., 2012). Meanwhile, H₂O₂ can induce VEGF expression on keratinocytes during the wound healing process. The content of hydrogen peroxide in honey helps in the healing process through the reaction of fenton which easily produces hydroxyl free radicals with a bactericidal effect (Majtan, J., 2011). Hydrogen peroxide is slowly formed because of the interaction between wound exudate and glucose oxidase contained in honey (Kwakman, P.H.S. and Zaat, S.A.J., 2012). Hydrogen peroxide can also attract leukocytes to the wound through a concentration gradient mechanism. Not only the antibacterial effect, hydrogen peroxide can also stimulate fibroblast proliferation and angiogenesis (Putri, N.A. and Asparini, R.R., 2017).

Despite the data result is not significant, the research hypothesis came from honey can affect on

wound healing observed from VEGF expressions and the number of neovascularization according to research conducted by Munshi (Munshi, R. et al., 2014) which shows that honey contains hydrogen peroxide and flavonoids that can increase the VEGF expression, ECM formation, as well as the formation of new blood vessels (Boukraâ, L., 2013).

Physiologically, the formation process of new blood vessels occurs in the proliferative phase which begins around day 4 to day 21 after injury (Zulfitri, A. et al., 2012). In this phase, the fibrin matrix that is dominated by platelets and macrophages is gradually replaced by granulation tissue composed of collections of fibroblasts, macrophages, and endothelial cells that make up the extracellular matrix and neovascular (Darby, I.A. et al., 2016). Macrophages produce proangiogenic factors such as vascular endothelial growth factor (VEGF), fibroblasts growth factor (FGF)-2, angiopoietin-1 and thrombospondin which will stimulate endothelial cells to form neovascular through the process of angiogenesis which is the formation of new blood vessels that replace damaged blood vessels (Stephenson, J.A. et al., 2013).

However, the effect of honey on burn healing process in microscopic observation from the number of fibroblasts was not as good as microscopic observation focused in VEGF expression and the number of neovascularization. Fibroblasts research data shows honey treatment group had a mean lower than the negative control group without treatment after induction burns, although the difference is not too far away. This shows the honey does not have the effect of healing for burns in terms of the number of fibroblasts due at the time of making preparations network research conducted on the 14th day after the induced burns. Previous research revealed that fibroblasts appears first on day 4 and reach its peak on day 7. On day 4 the beginning of the proliferative phase, which occurs on the surface of epithelial proliferation of blood clots, fibroblasts derived from the walls of the alveolar bone began to proliferate and spread into the blood clot. Meanwhile, on day 14 the number of fibroblasts likelihood decreased and replaced by extracellular matrix produced include fibronectin matrix, hyaluronic acid, glycosaminoglycans (Syamsuhidayat, R., 2010).

Burn treatment in this study conducted with an open wound condition that can affect the burn healing process. This is because wound care with an open condition causing injuries in a dry environment. According to research Junker (Svendsen, A.J. et al., 2013) wounds in a dry environment is no better than a humid environment due wound in a moist environment

can stimulate an increase in growth factors, stimulating the proliferation and migration of macrophages and fibroblasts cells so as to accelerate wound healing. Based on this, the wound in a dry environment will not support the proliferation and migration of fibroblasts to the optimum, so that when viewed from the number of fibroblasts in this study honey does not give results consistent with the hypothesis.

Results of Post Hoc LSD test on microscopic observations from the number of neovascularization showed that the Bioplacenton group provided significant burn healing with the negative group. The content on Bioplacenton® placenta extract can boost growth factor beta (TGF- β) in the early phase of wound healing and increased vascular endothelial growth factor (VEGF) in the final phase, triggering the formation of new tissue (Wu, J. et al., 2012). These results are in accordance with research conducted by Dewi (Dewi, S.P., 2010) which states Bioplacenton® activity plays a role in stimulating the regeneration of cells such as stimulating fibrocollagen re-epithelization and formation of connective tissue and prevent infection in wounds that inhibit wound curative process. Meanwhile, the result of post hoc LSD test in the Bioplacenton® group with the honey group did not show a significant difference. This is because honey and Bioplacenton® can provide an effect in second degree burn healing with the ability to stimulate angiogenesis.

CONCLUSIONS

Honey has a proangiogenic ability which is quite visible even though on the statistical test still show insignificant value, which honey can provide an effect on second degree burn healing in Wistar rats in terms of neovascularization as well as Bioplacenton®. On the other hand, honey did not show its ability as a profibroblasts in this study.

ACKNOWLEDGEMENT

Department of Histology, Faculty of Medicine, Diponegoro University, Semarang, Anatomical Pathology Laboratory of Dr. Kariadi General Hospital Medical Center, Semarang and Department of Anatomical Pathology, Faculty of Medicine, Diponegoro University, Semarang.

REFERENCES

- Barbara, A.B. et al. (2013) Willard and spackman's occupational therapy. 12 ed. Philadelphia: Wolters Kluwer Health.
- Boukraâ, L. (2013) Honey in traditional and modern

Almas, et al.

medicine. Boca Raton, FL: CRC Press.

- Christy, E. Manyi-Loh, Clarke, A. M. and Ndip, R. N. (2012) "An overview of honey: Therapeutic properties and contribution in nutrition and human health," *African Journal of Microbiology Research*, 5(9), hal. 844–852. doi: 10.5897/ajmr10.008.
- Dai, T. et al. (2010) "Topical Antimicrobials for Burn Wound Infections," *Recent Pat Antiinfect Drug Discov*, 5(2), hal. 124–51.
- Darby, I.A. et al. (2016) "The myofibroblast, a key cell in normal and pathological tissue repair," *Cell Mol Life Sci*, 73(6), hal. 1145–57.
- Dewi, S. P. (2010) Perbedaan Efek Pemberian Lendir Bekicot (*Achatina fulica*) dan Gel Bioplacenton TM terhadap Penyembuhan Luka Bersih pada Tikus Putih. Surakarta: Fakultas Kedokteran Universitas Sebelas Maret.
- Fatmawati, H., Rudijanto, A. and Indra, M. R. (2010) "Pengaruh Likopen terhadap Penurunan Aktivitas Nuclear Factor kappa Beta (NF- κ B) dan Ekspresi Intracelular Cell Adhesion Molecule-1 (ICAM-1) pada Kultur HUVECs yang Dipapar Leptin The Role Of Lycopene to Nuclear Factor Kappa Beta (Nf- κ B) Activities and on Leptin-Induced Endothelial Cell," 11(2), hal. 143–150.
- Frans, J. B. (2013) Sehat dengan Terapi Lebah. Elex Media Komputindo.
- Fromm, D. (2011) Principles of Surgery, *Archives of Surgery*. doi: 10.1001/archsurg.1975.01360120080021.
- Halim, A., Singh, K. K. and Sukur, S. (2011) "Evaluations of bacterial contaminated full thickness burn wound healing in Sprague Dawley rats Treated with Tualang honey," *Indian Journal of Plastic Surgery*, 44(1), hal. 112. doi: 10.4103/0970-0358.81459.
- Kwakman, P. H. S. and Zaat, S. A. J. (2012) "Antibacterial components of honey," *IUBMB Life*, 64(1), hal. 48–55. doi: 10.1002/iub.578.
- Majtan, J. (2011) "Methylglyoxal - A potential risk factor of manuka honey in healing of diabetic ulcers," *Evidence-based Complement Altern Med*, 2011, hal. 5–10.
- Mobayyen, M. et al. (2017) "Partial-thickness burn wounds healing by topical treatment," *Medicine*, 96(9), hal. e6168. doi: 10.1097/md.0000000000006168.
- Munshi, R. et al. (2014) "Exploration of the Angiogenic Potential of Honey Exploration of the Angiogenic Potential of," *Br. J. Pharm. Res.*, 4, hal. 477–489. doi: 10.9734/BJPR/2014/6930.
- Putri, N.A. and Asparini, R.R. (2017) "Peran Madu dalam Menghambat Pertumbuhan Bakteri pada Luka Bakar," *Fakultas Kedokteran Universitas Muhammadiyah Malang*, 13(2), hal. 63–68.
- Rao, P. V., Salleh, N. and Gan, S. H. (2016) "Biological and therapeutic effects of honey produced by honey bees and stingless bees: a comparative review," *Revista Brasileira de Farmacognosia. Sociedade Brasileira de Farmacognosia*, 1(26), hal. 1–8. doi: 10.1016/j.bjp.2016.01.012.
- Specht, E. et al. (2015) "Comparison of immunoreactive score, HER2/neu score and H score for the immunohistochemical evaluation of somatostatin receptors in bronchopulmonary neuroendocrine neoplasms," *Histopathology*, 67, hal. 368–377. doi: <https://doi.org/10.1111/his.12662>.
- Stephenson, J.A. et al. (2013) "Tumour angiogenesis: a growth area—from John Hunter to Judah Folkman and beyond," *J Cancer Res*, 2013(895019), hal. 1–6. doi: 10.1155/2013/895019.
- Svendsen, A. J. et al. (2013) "On the Origin of Rheumatoid Arthritis: The Impact of Environment and Genes — A Population Based Twin Study," *Plos One*, 8(2), hal. 1–7. doi: 10.1371/journal.pone.0057304.
- Syamsuhidayat, R. (2010) Buku Ajar Ilmu Bedah, Edisi III. Jakarta: EGC.
- Vinay Kumar, Abdul K. Abbas, Nelson Fausto, J. A. (2012) Tissue renewal, regeneration, and repair. Elsevier Inc.
- Wang, N. et al. (2012) "Ellagic acid , a phenolic compound , exerts anti-angiogenesis effects via VEGFR-2 signaling pathway in breast cancer," *Breast Cancer Res Treat*, 134, hal. 943–955. doi: 10.1007/s10549-012-1977-9.
- Wardhana, A. et al. (2017) "The epidemiology of burns in Indonesia's national referral burn center from 2013 to 2015," *Burns Open*, 1(2), hal. 67–73. doi: 10.1016/j.burnso.2017.08.002.
- WHO. (2014). Burns: Violence and injury prevention. Tersedia pada: https://www.who.int/violence_injury_prevention/other_injury/burns/en/ (Diakses: 3 Maret 2019).
- Wu, J. et al. (2012) "NIH Public Access," *Cancer Lett*, 308(1), hal. 43–53. doi: 10.1016/j.canlet.2011.04.012.Caffeic.
- Zulfitri, A. et al. (2012) "The Effect of extract Binahong leaf gel (*Anredera cordifolia*) to improve guinea pigs (*Cavia cobaya*) fibroblast cell and capillaries number over wound healing process after tooth extraction," *Journal Media Oral Biology Dental Journal*, 4(2).