

RESEARCH ARTICLE

The Effect of CMCE Propolis Extract Administrations on Interleukin-1 (IL-1) Levels and the Hepatocyte Histopathological Findings of Rats' Induced with CCl₄

Catur Retno Lestari^{1*}, Titiek Sumarawati¹, Taufiqurrachman Nasihun¹

¹Magister of Biomedical Sciences, Faculty of Medicine Sultan Agung Islamic University, Semarang

Corresponding author email: caturretno.lestari@gmail.com / +6285839161260

ABSTRACT

Introduction: Liver exposure to toxic substances will disrupt the metabolic system. Carbon tetrachloride (CCl₄) is a hepatotoxic substance causing a liver damage. Continuous multi-stage countercurrent extraction (CMCE) propolis extract contains active balsamic substances, caffeic acid, phenethyl esters and flavonoids. **Objective:** to prove the effect of CMCE propolis extract on IL-1 levels and the hepatocyte histopathology findings of male wistar rats' induced by CCl₄.

Methods: In the posttest only control group design, the total sample of 28 rats was divided into 4 groups: positive control group (K-0; standard feed); group P-1 (propolis 3.6 mg/200 g); P-2 (propolis 7.2 mg/200 gr and P-3 (propolis 14.4 mg/200 g) were respectively given for 14 days, yet those on the 14th day were given CCl₄. The IL-1 level was measured with the ELISA method, while the male wistar rats' hepatocyte histopathology findings was determined by the HE staining methods. IL-1 levels were analyzed using One Way Anova test, followed by the Post Hoc LSD test. Hepatic cell histopathology was analyzed using Kruskal Wallis, followed by Mann-Whitney U.

Results: Post Hoc LSD analysis shows that the levels of IL-1 in P-1 (983.54 ± 19.67), P-2 (841.58 ± 19.47), and P-3 (755.50 ± 31.63) are significantly lower than those in K-0 (1131.69 ± 14.91) with $p < 0.05$. Mann-Whitney U analysis shows that the hepatocyte histopathology in the P-1 group (2.55 ± 0.39), P-2 (1.24 ± 0.94) and P-3 (1.20 ± 0.93) is significantly lower than that in K-0 (2.94 ± 0.16) with $p < 0.05$.

Conclusion: The administration of CMCE propolis extract may reduce IL-1 levels and improve the male wistar rats' hepatic cell histopathology induced with carbon tetrachloride (CCl₄).

Keywords: CMCE Propolis extract, IL-1, histopathology hepatic cell.

ABSTRAK

Latar Belakang: Hepar yang terpapar oleh bahan toksik akan mengganggu sistem metabolisme. Salah satu zat hepatotoksik yang menyebabkan kerusakan hepar adalah karbon tetraklorida (CCL₄). Ekstrak CMCE propolis mengandung zat aktif balsamic, senyawa polifenol caffeic acid phenethyl ester, dan flavonoid. **Tujuan:** membuktikan pengaruh pemberian ekstrak CMCE propolis terhadap kadar IL-1 dan gambaran histopatologi sel hepar tikus jantan wistar yang di induksi CCl₄.

Metode: Penelitian eksperimental dengan *post test only control group design*, menggunakan sampel sebanyak 28 ekor tikus dibagi menjadi 4 kelompok: kelompok kontrol positif (K-0; pakan standart); kelompok P-1 (3,6 mg/200gr); P-2 (7,2 mg/200gr) dan P-3 (14,4 mg/200gr) masing-masing mendapatkan ekstrak CMCE selama 14 hari, selanjutnya pada hari ke-14 diberikan CCL₄. Kadar IL-1 diukur menggunakan metode ELISA, sedangkan gambaran histopatologi diukur dengan preparat histopatologi sel hepar dengan perwarnaan HE. Analisis kadar IL-1 menggunakan uji *One Way Anova* dilanjutkan dengan uji *Post Hoc LSD*. Sedangkan analisis gambaran histopatologi sel hepar menggunakan *Kruskal Wallis* dilanjutkan *Mann-Whitney U*.

Hasil: Analisis Post Hoc LSD menunjukkan bahwa kadar IL-1 kelompok P-1 (983,54 ± 19,67), P-2 (841,58 ± 19,47), dan P-3 (755,50 ± 31,63) lebih rendah signifikan dibanding K-0 (1131,69 ± 14,91), $p < 0,05$. Analisis *Mann-Whitney U* menunjukkan bahwa histopatologi sel hepar pada kelompok P-1 (2,55 ± 0,39), P-2 (1,24 ± 0,94), dan P-3 (1,20 ± 0,93) lebih rendah signifikan daripada K-0 (2,94 ± 0,16), $p < 0,05$.

Kesimpulan: Pemberian ekstrak CMCE propolis mampu menurunkan kadar IL-1 dan perbaikan gambaran histopatologi sel hepar tikus jantan wistar yang di induksi karbon tetraklorida (CCl₄).

Kata Kunci: Ekstrak CMCE Propolis, Kadar IL-1, Histopatologi Sel Hepar.

INTRODUCTION

Free radical or reactive oxygen species (ROS) plays an important role in oxidative stress and pathophysiology of various diseases, including liver disease and function disorder (Maulina, 2015; Nunekpeku et al., 2018).

Damage to hepatic cells resulting from active toxic drugs and substances may be in the form of hepatocyte necrosis, cholestasis, protein synthesis disorder and fat accumulation in cell (steatosis). Hepatocyte damage in the form of hydropic degeneration is followed with

Lestari, et al.

fat degeneration, causing the cell to die or necrosis (Bagus and Winaya, 2011). The hepatic damage process may be prevented with antioxidant (Linawati, 2018). Propolis is a substance containing various antioxidant thought to be able to suppress free radicals (Maulina, 2015). However, it is still unknown whether propolis may prevent hepatic damage resulting from exposure to free radicals, thus needs further research.

Liver disease is a global health problem, more than 350 million people throughout the world have chronic hepatitis (Park et al., 2010). The data of study on the Assessment of Renal Function in Chronic Liver Disease in 2015 show that the morbidity of liver disease in the world is quite high ('Study on Assessment of Renal Function in Chronic Liver Disease', 2015). WHO's 2017 report also states that liver disease cause the eighth highest number of deaths in Indonesia, with a death rate of 3.37 %, or about 55,860 people (Fatima et al., 2017). Most deaths caused by hepatitis virus in 2015, are caused by chronic liver disease (720,000 deaths due to cirrhosis) and primary liver cancer (470,000 death due to hepatocellular carcinoma) (WHO, 2017). Hepatitis patients in Indonesia are about 0.7-1.2, the third highest number after India and China (Kemenkes RI, 2014). The data of the Ministry of Health of the Republic of Indonesia (2010) states that there are about 130 people having hepatitis B and 7 million people having hepatitis C, 50% potentially have chronic hepatitis and 10% potentially have liver cirrhosis and liver cancer (Kemenkes RI, 2010). Liver is a central organ in the body metabolism (Rohmatin et al., 2012). Liver is part of gastrointestinal tract exposed to toxic substances (Lengkung, 2013). One of hepatotoxic substances causing damage to hepatic cells is carbon tetrachloride (CCl₄) (Krisnansari et al., 2014). CCl₄ administration may cause oxidative stress process, hormonal balance disorder and acute and chronic inflammatory reaction triggering release of pro-inflammatory cytokines, including interleukin-1 (Boll M, et al. 2001).

Propolis extract contains antioxidant which may repair damaged hepatic cells. Research result shows that propolis extracts 0.054 gr and 0.108 gr show hepatoprotective activity on damaged liver induced by CCl₄ as shown with decreased level of IL-6, superoxide dismutase (SOD) and lower percentage of damage to hepatocyte (Krisnansari et al., 2014). Administration of propolis extract 8.3mg improves the quality of spermatozoa and decreases the MDA level of male Wistar rat's epididymis exposed to cigarette smoke (Hoesada et al., 2016). A propolis extract with extraction system "continuous multi-

stage countercurrent extraction" (CMCE) is a super-extraction of poplar propolis. Research result shows that DBD patients administered with propolis extract have significantly lower pro-inflammatory cytokines than those not administered with propolis. Propolis may also increase macrophage activity related to cytokine production such as IL-1 and TNF- α in mouse (Soroy et al., 2014).

Propolis extract has main active biological substances, found in balsamic content and included in polifenol caffeic acid phenethyl ester (CAPE), flavonoid (chrysin, catechin, galangin), derivative of stilbene (resveratrol), and fatty acid substances. Propolis extract also serves as immunoregulator which may increase immunity status, thus it may protect hepatic cells from damage, by suppressing kupffer cell activity in producing ROS and cytokines, worsening inflammatory condition (Eteraf-Oskouei and Najafi, 2013). CAPE significantly inhibits cytokine and lymphokine production, including TNF- α , IL-2, IL-10, IL-12 and IFN, and inhibits T-cell proliferation (Perez et al., 2010). Flavonoid will inhibit pro-inflammatory cytokines such as TNF- α , IL-1 α and IL-2. Pro-inflammatory cytokine, IL-1, IL-6 and TNF- α are responsible for body's metabolic change and pathogen attack (Kusdalinah et al., 2014). Referring to the various data, research needs to be conducted to examine whether CMCE propolis extract administration influences decrease in IL-1 level and improved hepatocyte histopathology of male wistar rat's (*rattus norvegicus*) induced by carbon tetrachloride (CCl₄).

METHODS

This experimental research employed a "Post Test Only Control Group Design". The research population was 28 male wistar rats (*Rattus norvegicus*) (8 weeks old, 180-200gr of body weight), divided into 4 groups consisting of positive control group (K-0), given CCl₄ at dose 0.4 ml/200gr on day 14, and treatment groups (P-1, P-2, and P-3) given propolis extract respectively at doses 3.6 mg/200 g, 7.2 mg/200 g and 14.4 mg/200 g for 14 days. The rats were given 0.4 ml/gr of CCl₄ on day 14. The propolis extract used was extracted through four stages known as Continuous Multi Stage Countercurrent Extraction Process (CMCE). The IL-1 level was examined using ELISA kit and the hepatocyte histopathology findings was examined using Hematoxilin Eosin (HE) staining. This research was conducted at the Laboratory of Food and Nutrition Study (PSPG) of Gajah Mada University, Yogyakarta and Sultan Agung Islamic Hospital, Semarang. The research was conducted upon approval from the

Committee of Bioethics of Faculty of Medicine, Sultan Agung Islamic University, Semarang under No. 269/V/2019/Komisi bioetik.

Hematoxylin Eosin (HE) Preparation Making Method

Chloroform was used to anesthetized rats, since not disrupting liver quality. The liver were then cut and stored in petri dish containing buffer formalin solution 10%. The liver were taken into paraffin block and processed to be histological preparation using Hematoxylin-Eosin (HE) staining method. Two histological preparations were made out of each rat from respective group. The histological preparations were read using a light microscope at 400x magnification. Hepatocyte was checked for its damaged score.

Interleukin-1 (IL-1) Measurement

The IL-1 level was measured using the ELISA method. Thirty serum samples of male wistar rats were used. The IL-1 examination principle was that the samples were made to react with antibody containing specific antibody against IL-1, added with Horseradish Peroxidase (HRP) and Avidin incubated for 1 hour at 37°C. The IL-1 level was measured using spectrophotometer at wavelength 450nm.

Statistical Analysis

The IL-1 level data were analyzed using One Way Anova, followed with a Post Hoc LSD test. Meanwhile, hepatocyte damage score were analyzed using Kruskal Wallis, followed with Mann-Whitney U. The analysis result was significant if p value < 0.05

RESULTS

Propolis extract was administered in this research for 14 days and CCl₄ was administered on day 14 to male wistar rats.

This research result shows that the highest mean

IL-1 level is that of group K-0, followed with group P-1, group P-2, and the lowest mean IL-1 level is of group P-3. Considering that all of the IL-1 level data are normally distributed (Shapiro Wilk $p > 0.05$) and homogenous (Levene's Test $p > 0.05$), the statistical analysis employed is the One Way Anova. The anova test result shows significant difference between the groups, $p < 0.05$.

This research result also shows that the highest mean damage score occurs with group K-0, followed with group P-1, group P-2 and the lowest occurs with group P-3 (figure 2). Considering that the mean data of hepatic cell damage are not normally distributed (Shapiro Wilk $p > 0.05$) and not homogenous (Levene's Test $p > 0.05$), Kruskal Wallis test is conducted. The analysis result shows there is significant difference between the groups, $p < 0.05$. Further, the post-hoc and Mann-Whitney U tests are conducted to identify which group is significantly different, as outlined below.

Interleukin-1 (IL-1) Level

The Post Hoc test shows that the IL-1 levels of groups P-1, P-2 and P-3 are significantly lower than that of group K-0, $p < 0.05$. Meanwhile, the IL-1 level of group P-3 is significantly lower than that of groups P-1 and P-2, $p < 0.05$. Similarly, the IL-1 level of group P-2 is lower than that of group P-1, $p < 0.05$ (figure 1). The Post Hoc LSD test result shows that administration of propolis extract at doses 3.6 mg/200 g, 7.2 mg/200 g and 14.4 mg/200 g may reduce IL-1 level in male wistar rats induced with carbon tetrachloride (CCl₄).

Hepatocyte Damage Score

Mann-Whitney analysis shows that the hepatocyte damage scores of groups P-1, P-2 and P-3 are significantly lower than that with K-0, $p < 0.05$. Meanwhile, the hepatocyte damage scores in group P-3 and P-2 are significantly lower than that with group P-1, $p < 0.05$. Slightly different from IL-1 level, the hepatocyte

Table 1. Result of statistical analysis on the measurement of IL-1 level and Hepatocyte Histopathology Score

Variable	Group				P
	K-0	P-1	P-2	P-3	
	N=6 $\chi(\pm SD)$	N=6 $\chi(\pm SD)$	N=6 $\chi(\pm SD)$	N=6 $\chi(\pm SD)$	
IL-1 Level (pg/ml)	1131.692 ± 14.913	983.544 ± 19.673	841.588 ± 19.479	755.502 ± 31.632	$> 0.05^*$ 0.231** 0.000***
Hepatocyte Damage Score (%)	2.946 ± 0.165	2.551 ± 0.393	1.241 ± 0.944	1.210 ± 0.935	$< / > 0.05^*$ 0.000** 0.000****

Note: *Shapiro Wilk Test (normal), ** Levene's Test (homogenous), ***One Way Anova, ****Kruskal Wallis

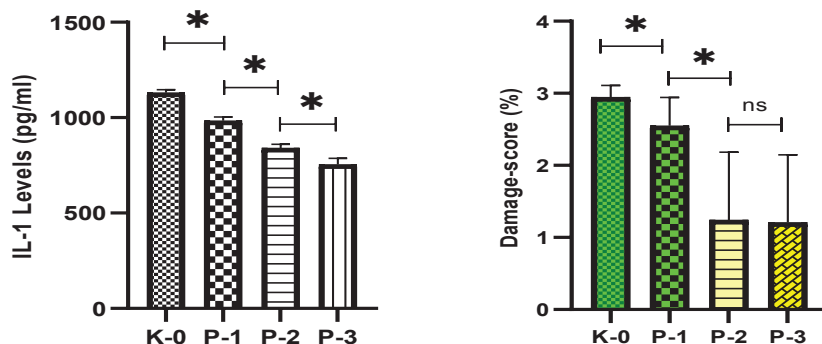


Figure 1. Post Hoc Statistical Analysis on IL-1 Level and Damage Score of Hepatic Cells. * $p < 0.05$; ns: not significant
 The hepatocyte histopathological findings of each treatment group is presented in Figure 1.

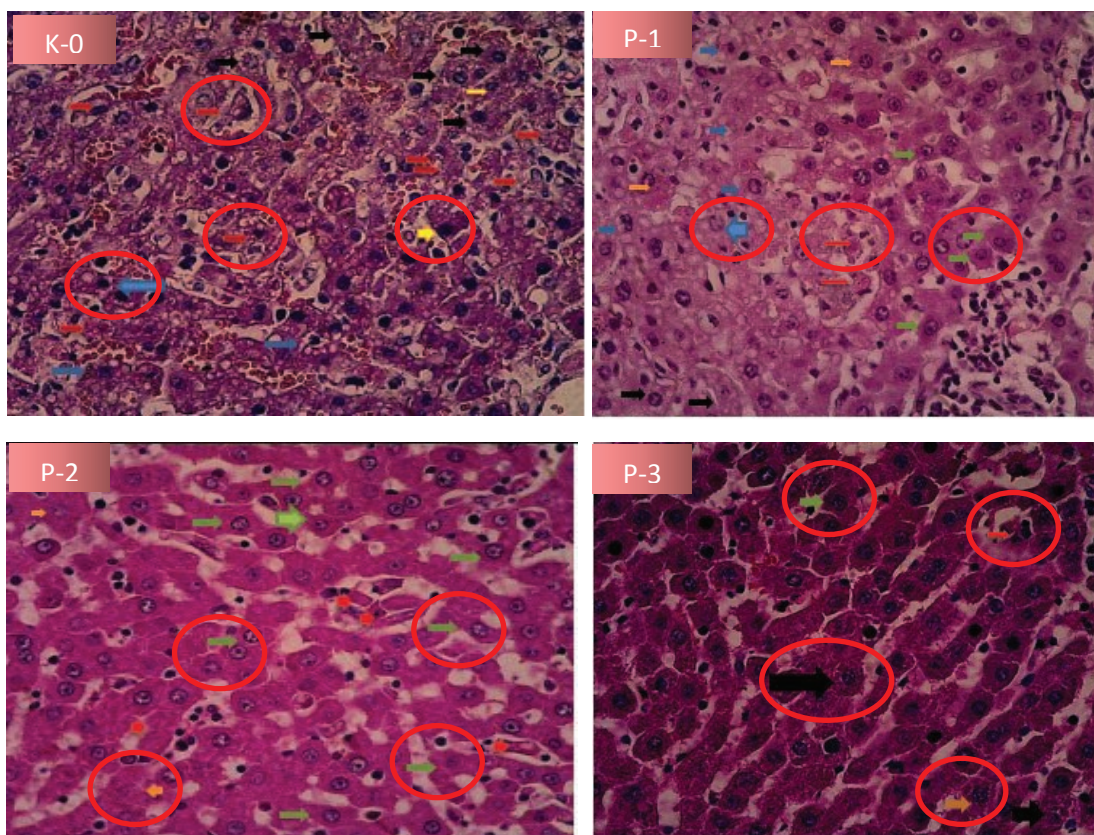


Figure 1. Histopathological Picture of Hepatic Cells with HE stain at 400x magnification:
 Normal Cell →; Parenchymatous degeneration →; Hydropic degeneration →; Fatty degeneration →; Necrosis →

Note:

K-0: Hepatic cell experiences parenchymatous degeneration (cell swelling, turbid cytoplasm), hydropic degeneration (2x cell swelling), fatty degeneration (cells get fatty) and nucleus death (necrosis).

P-1: Hepatic cell still experiences parenchymatous degeneration (cell swelling, turbid cytoplasm), nucleus shrinks but there are normal cells visible.

P-2: Hepatic cells seem to be more than normal cells, and cell picture is brighter.

P-3: There are normal cells, but experiencing hydropic degeneration (cell swelling) and there is nucleus death.

damage scores in P-3 is not significantly different from that with group P-2, $p > 0.05$ (figures 1 and 3). Based on the Mann-Whitney U test result of the hepatocyte damage scores, it is found that CMCE propolis extract administered at doses 3.6 mg/200 g, 7.2 mg/200 g and 14.4 mg/200 g may serve as hepatoprotector against

CCl4 injection.

DISCUSSION

The results of this research show that one administration of CCl4 at dose 0.4 ml/200 g on day 14 show significant damage to hepatocyte, as proven with

the hepatocyte damage score in group administered only with CCl₄ is significantly higher than that of groups P-1, P-2 and P-3. This research result conforms theory that hepatocyte damage resulting from CCl₄ is caused by free radicals, forming covalent bond with cell component or through lipid peroxidation (Boll M, et al. 2001). In addition, the hepatotoxic effect of CCl₄ may also be caused by oxygen partial pressure of the tissue stimulating formation of radicals CCl₃ and CHCL₂ followed with metabolite binding. In high oxygen partial pressure, CCl₄ may be changed to CCl₃-OO with a consequence of lipid peroxidation and trigger change from steatosis to apoptosis (Boll M, et al. 2001; De Groot et al. 1988). Further, exposure to CCl₄ at low dose evidently may also cause hepatocyte inflammation as marked with increased production of tumor necrosis factor (TNF- α) (Boll M, et al. 2001). Healthy hepatocyte are very insensitive to TNF- α , but more sensitive to inhibition of RNA and protein synthesis. Increased inflammation caused by exposure to CCl₄ may also potentially cause cancer formation (Boll M, et al. 2001).

This research result also shows that hepatocyte damage resulting from CCl₄ exposure may be prevented or repaired with propolis administration. The level of prevention of propolis administration may be stated pursuant to the dose administered, that the higher the dose, the lower the damage to hepatic cells is formed. In this research, with propolis extract administration at dose 3.6 mg/200 g, the damage to hepatocyte caused is also lower, even if it is significantly higher than that of the control. Meanwhile, with propolis administration at doses 7.2 mg/200 g and 14.4 mg/200 g, the damage to hepatocyte is far lower than that with propolis administration at dose 3.6 mg/200 g. This research result conforms to the research conducted by Timur et al. that propolis administration may repair damage to hepatic tissue of male wistar rats induced with paracetamol (Timur et al., 2017). Both CCl₄ and paracetamol may trigger lipid peroxidation and serve as important mediator of damage to hepatic cells. Lipid peroxidation may be suppressed with antioxidant supplementation such as propolis containing flavonoid, silymarin or vitamin E (Krisnansari et al., 2014). Since propolis extract is bee's product containing rich active material flavonoid and serving as antioxidant (Annis et al., 2017). Considering that pollutant is xenobiotic which is also of free radical, propolis extract may also serve to clear pollutant which has entered into the body (Prasetyo et al., 2011).

Hepatocyte damage resulting from CCl₄ exposure may also cause acute inflammation as

marked with increased level of proinflammator such as IL-1, IL-6 and TNF- α (Kamimura et al., 2003; Avitsur et al., 2006). This research result shows that propolis extract administered as doses 3.6 mg/200 g, 7.2 mg/200 g and 14.4 mg/200 g may decrease IL-1 level significantly. This research result illustrates that propolis has effect of repairing acute inflammation resulting from CCl₄ exposure. Phenolic substance in propolis able to protect cells structure from foreign organism attack. Propolis administered to mouse with cancer also evidently increases the levels of IL-1 and IL-6, which serve as tumor promoter. IL-1 and IL-6 increases TNF α levels. Along with INF α triggers tumoricidal macrophage. Therefore, increased level of proinflammatory markers with cytokine produced by TH1 (IFN α) may inhibit tumor growth. This is relevant, considering that propolis also contains CAPE which may inhibit deoxyribonucleic acid (DNA) activity, NF κ B transcription and activator protein-1 (AP-1), without degrading protein which inhibits NF κ B situated in cytoplasm. Referring to the data, we may conclude that propolis has immunomodulatory and anti-inflammatory activities (Soroy et al., 2014).

CONCLUSION

CMCE propolis extract administered at doses 3.6mg/200gr, 7.2mg/200gr and 14.4mg/200gr for 14 days decreases IL-1 level and repairs hepatic cell damage in male wistar rats (*Rattus norvegicus*) resulting from exposure to Carbon Tetrachloride (CCl₄).

CONFLICT OF INTEREST

There is no conflict of interest in this publication.

ACKNOWLEDGEMENT

We highly appreciate and express our gratitude to the staffs of the laboratory of food and nutrition study center of Gadjah Mada University and staffs of the laboratory of Pathology and Anatomy of RSI Sultan Agung Semarang for their hard work and guidance in maintaining and testing the samples throughout this research.

REFERENCES

- Akbari, A. R. 2015. pengaruh Pemberian Propolis Terhadap Gambaran Histopatologi Hepar Pada Mencit (*Mus musculus*) Jantan (Doctoral Dissertation, Universitas Airlangga).
- Alvina, A. 2016. Type IV collagen as marker of fibrosis in nonalcoholic liver disease. *Universa Medicina*, 29(2), 114-122.

Lestari, et al.

- Annis, F., Purnomo, H. and Balafif, F. 2017. Pengaruh Ekstrak Propolis terhadap Apoptosis melalui Ekspresi Brain-Derived Neurotrophic Factor (BDNF) pada Sel Otak Tikus Model Cedera Otak Traumatik The Effect of Propolis Extract Administration on Apoptosis through Brain-Derived Neurotrophic Factor, 29(3), pp. 209–215.
- Avitsur R; Hunzeker; J, Sheridan, J F. 2006. Role of early stress in the individual differences in host response to viral infection. *Brain, Behavior, and Immunity* 20: 339-348.
- Bagus, I. and Winaya, O. 2011. Kadar Perasan Kunyit yang Efektif Memperbaiki Kerusakan Hati Mencit yang Dipicu Karbon Tetrachlorida, 12(1), pp. 34–39.
- Basu, S. 2013. Carbon tetrachloride-induced lipid peroxidation : eicosanoid formation and their regulation by antioxidant nutrients, 189. doi: 10.1016/S0300-483X(03)00157-4.
- Bhadauria, M. 2012. Propolis prevents hepatorenal injury induced by chronic exposure to carbon tetrachloride', *Evidence-based Complementary and Alternative Medicine*, 2012. doi: 10.1155/2012/235358.
- Boll M, Weber LWD, Becker E, Stampfl A. Mechanism of Carbon Tetrachloride-Induced Hepatotoxicity. *Hepatocellular Damage by Reactive Carbon Tetrachloride Metabolites*. 2001. *Naturforsch.* 56c 6 49-659.
- D, A. C., Ali, M. and Purnomo, H. 2016. Efek Ekstrak Propolis terhadap Ekspresi TNF- α , Apoptosis dan Nekrosis Jaringan Otak Tikus Model Traumatic Brain Injury (TBI) The Effects of Propolis Extract on Brain TNF- α Expression, Apoptosis and Necrosis in Rat Model of Traumatic Brain Injury, 29(2), pp. 117–124.
- De Groot H., Littauer A., Hugo-Wissemann D., Wissemann P. and Noll T. (1988), Lipid peroxidation and cell viability in isolated hepatocytes in a redesigned oxystat system: Evaluation of the hypothesis that lipid peroxidation, preferentially induced at low oxygen partial pressure, is decisive for CC14 liver cell injury. *Arch. Biochem. Biophys.* 264, 591-599.
- Krisnansari, D., Sulisty, H., & Kusdaryantoi, W. D. 2014. Potensi Hepatoprotektor Propolis Terhadap Hepar Tikus Putih (*Rattus Norvegicus*) Yang Diinduksi Karbon Tetrachlorida. *Jurnal Ners*, 9, 270-78.
- Hoesada, I., Nasihun, T., & Isradji, I. 2016. The Effect of Propolis Extract on MDA Levels (Malondialdehyde) and Sperm Quality on Epididimis (Experimental Study on Wistar Strain Male Rats Exposed to Kretek Cigarettes). *Sains Medika: Jurnal Kedokteran dan Kesehatan*, 7(1), 09-14.
- Eteraf-Oskouei, T. and Najafi, M. 2013. Traditional and modern uses of natural honey in human diseases: A review, *Iranian Journal of Basic Medical Sciences*, 16(6). doi: 10.22038/IJBMS.2013.988.
- Fatima, A. et al. 2017. Comparison of Terlipressin with Octreotide in Management of Acute Variceal Bleed in Patients with Liver Cirrhosis, 21(3), pp. 191–196.
- Ferreira, E. A. et al. 2010. Potent hepatoprotective effect in CCl₄ -induced hepatic injury in mice of phloroacetophenone, 2820. doi: 10.3402/ljm.v5i0.4891.
- Bhara, M. 2015. Pengaruh pemberian kopi dosis bertingkat per oral 30 hari terhadap gambaran histologi hepar tikus wistar (Doctoral dissertation, Medical Faculty).
- Kamimura, D; Ishihara, K; Hirano, T. 2003. IL-6 signal transduction and its physiological roles: the orchestration model. *Reviews of Physiology, Pharmacology* 149: 1-38.
- Khotimah, C. 2015. Pengaruh Pemberian Propolis Terhadap Jumlah Dan Hitung Jenis Leukosit Darah Mencit (*Mus Musculus*) Jantan. *Journal Of Basic Medicine Veterinary*. Vol.4 No.1, Hal. 28-34.
- Kusdalinah, Andrew J, N. W. 2014. Ekstrak Buah Naga Daging Merah (*Hylocereus polyrhizus*) terhadap Berat Badan, Indeks Fagositosis Makrofag dan Produksi Nitrit Oksida Makrofag (Studi pada Mencit yang Diinfeksi *Salmonella typhimurium*), *Jurnal Gizi Indonesia*, 2(2), pp. 73–77.
- Kementerian Kesehatan RI. 2014. *Situasi Dan Analisis Hepatitis Pusat Data Dan Informasi*. Jakarta.
- Kementerian Kesehatan RI. 2010. *Riset Kesehatan Dasar*. Jakarta.
- Lengkong, A. B. 2013. Gambaran Histopatologik Hati Tikus Wistar Yang Diinduksi CCL4 dan diberi Air Rebusan Tanaman Cakar Ayam (*Selaginella*

- Doederleini Hieron). *Jurnal e-Biomedik*, 1(2).
- Linawati. 2018. Purple Cabbage Extract Cream Effect on Erythema Score of Male Wistar Rats Back Skin Exposed to UV-B Radiation. *Biomedical and Pharmacology Journal*, 11(1), 343-351.
- Maulina, Meutia. 2013. Pengaruh Pemberian Xanthone Terhadap Gambaran Histopatologi Sel Hepar Tikus Putih Jantan (*Rattus Norvegicus*) Yang Diinduksi Karbon Tetraklorida (CCl₄) Penelitian Eksperimental Laboratorik. Diss. Universitas Airlangga.
- Krisnansari, D., Sulisty, H., & Ati, V. R. B. 2014. Efek Propolis Terhadap Fungsi dan Perlemakan Hati Tikus Putih (*Rattus norvegicus*) Model Hiperkolesterolemia. *Nutrition and Food Research*, 37(1), 77-85.
- Nunekpeku, W. et al. 2018. Screening for total antioxidant activity, flavonoids and phenolics variability in forty-five accessions of roselle (*Hibiscus sabdariffa* L.), 17(22), pp. 694–699. doi: 10.5897/AJB2017.16286.
- Park, C. M. et al. 2010. Amelioration of Oxidative Stress by Dandelion Extract through CYP2E1 Suppression against Acute Liver Injury Induced by Carbon Tetrachloride in Sprague-Dawley Rats', 1353), pp. 1347–1353.
- Perez, A. B. et al. 2010. Tumor necrosis factor- α , transforming growth factor- β 1, and interleukin-10 gene polymorphisms: Implication in protection or susceptibility to dengue hemorrhagic fever', *Human Immunology*. Elsevier Inc., 71(11), pp. 1135–1140. doi: 10.1016/j.humimm.2010.08.004.
- Prasetyo, D. H., Suparyanti, E. L. and Guntur, A. H. 2011. Ekstrak Etanol Propolis Isolat Menurunkan Derajat Inflamasi dan Kadar Malondialdehid pada Serum Tikus Model Sepsis Ethanol extract of Propolis Reduces the Level of Inflammation and Serum Malondialdehyde in Sepsis Rats Model, 45(36), pp. 161–166.
- Rohmatin, A. R., Susetyarini, E. and Hadi, S. 2012. Kerusakan Sel Hepar Tikus Putih Jantan (*Rattus norvegicus*) yang di Induksi Karbon Tetraklorida (CCl₄) setelah Diberi Ekstrak Etanol Bawang Dayak (*Eleutherine palmifolia* Merr.) The Damage of Hepar Cells of White Male Mice (*Rattus norvegicus*) which, pp. 942–947.
- Soroy, L. et al. 2014. The effect of a unique propolis compound (propoelixTM) on clinical outcomes in patients with dengue hemorrhagic fever, *Infection and Drug Resistance*, 7, pp. 323–329. doi: 10.2147/IDR.S71505.
- Tendean, L. 2016. Perbandingan kualitas spermatozoa tikus wistar (*rattus norvegicus*) yang diberi paparan asap rokok dengan asap rokok elektronik Misael Tooy Kandidat skripsi Fakultas Kedokteran Universitas Sam Ratulangi Manado Peraturan Pemerintah Republik Indonesia, 4.
- Timur, J. et al. 2017. Efek Pemberian Propolis terhadap Gambaran Histopatologi Hepar Tikus Putih yang diberi Parasetamol Of White Rats Given Paracetamol, 9(1), pp. 87–93. doi: 10.21531/bulvet.2017.9.1.87.
- WHO. 2017. Study on Assessment of Renal Function in Chronic Liver Disease (2015), pp. 9–12. doi: 10.7860/JCDR/2015/11423.5658.