

## Toxic Optic Neuropathy Due to Methanol in Dr. Sardjito Hospital (Lapen Intoxication)

### Case Series

### *Kasus Neuropati Optik Toksik karena Methanol di RSUD dr. Sardjito (Intoksikasi Lapen)*

Nika Bellarinatasari<sup>1\*</sup>, Hartono<sup>2</sup>

#### ABSTRACT

**Purpose:** To describe three cases of toxic optic neuropathy due to methanol.

**Method:** Case series

**Results:** There were 3 cases in Dr. Sardjito Hospital. First case, a male, 28 years old, drunk three glasses of lapen about 1 week before he went to hospital. At his first time he came, his vision was no light perception (NLP) for both eyes. Then he hospitalized for a week and got 48 mg methyl prednisolone orally. After 1 month, his vision of the both eyes didn't improve. From the sample of his drink, we found methanol 4,38% and ethanol 4,91%. Second case, a male, 46 years old, drunk one glass of lapen about 4 days before he went to hospital. His vision was NLP for both eyes. Like the first case, he got the same management, and after 1 month his vision still didn't improve. From the sample of his drink, we found methanol 12,41% and ethanol 3,74%. Third case, a male, 21 years old, drunk more than 3 glasses of combination of Vodka, lapen, Kratingdaeng, and beer. The visual acuity were 3/60 for the right eye and hand movement (HM) for the left eye. Like the cases before, he got the same management, and after 1 month his vision had improved became 3/60 for the right eye and 2,5/60 for the left eye. Unfortunately, we didn't have the sample of his drink.

**Conclusion:** Lapen is Yogyakarta home made beverage which contains with methanol. Methanol is toxic liquid that cause toxic optic neuropathy. Blindness is the most common symptom and permanent (Sains Medika, 3(2):177-184).

**Key words :** Methanol; Blindness; Toxic optic neuropathy

#### ABSTRAK

**Latar belakang:** laporan kasus ini bertujuan untuk mendeskripsikan kasus Neuropati Optik Toksik karena methanol.

**Metode:** Case series

**Hasil:** Ada 3 kasus di Rumah Sakit Dr. Sardjito. Pertama seorang laki-laki berusia 28 tahun meminum 3 gelas lapen sekitar satu minggu sebelum dia kerumahnya. Saat pertama datang, dia mengalami NLP (*no light perception*) dikedua matanya. Kemudian dia dirawat dirumah sakit selama satu minggu dan diberikan methyl prednisolone 48. setelah satu bulan, kedua matanya tidak membaik. Dari sampel minumannya, diketahui mengandung methanol 4.38% dan ethanol 4.91%. Kasus kedua, seorang laki-laki berusia 46 tahun meminum satu gelas lapen sekitar 4 hari sebelum dia kerumahnya mengalami NLP dikedua matanya. Seperti kasus sebelumnya, setelah mendapatkan perawatan yang sama, penglihatannya tidak membaik methanol 12.41% and ethanol 3.74%. Kasus ketiga seorang laki-laki 21 tahun minum lebih dari 3 gelas kombinasi Vodka, Lapen, Kratingdaeng dan bir. Akuitas penglihatannya 3/60 untuk mata kanan dan HM (*hand movement*) untuk mata kiri. Seperti kasus sebelumnya dia mendapatkan pengobatan yang sama dan setelah satu bulan penglihatannya membaik menjadi 3/60 untuk mata kanan dan 2.5/60 untuk mata kiri. Pada penelitian ini tidak didapatkan sampel minumannya.

**Kesimpulan:** Lapen adalah minuman tradisional yang mengandung methanol. Methanol adalah cairan beracun yang menyebabkan toksik neuropati optik. Kebutaan adalah gejala yang paling sering dijumpai dan bersifat permanen (Sains Medika, 3(2):177-184).

**Kata kunci:** metanol, kebutaan, Neuropati Optik Toksik

---

1 Bagian Mata Fakultas Kedokteran Universitas Islam Sultan Agung (UNISSULA)

## INTRODUCTION

Lapen is illegal alcohol beverage that is made by home industry in Yogyakarta. Because of home industry, there is no quality controlled like in fabric industry. Lapen can be found at stall or small store easily. Because of its low cost, a lot of people from low economic level consume it. But later, lapen has become popular, because a lot of people complain blurred vision or blind or even die after drunk lapen.

NA-DFC (The National Agency of Drug and Food Control) Yogyakarta had tested samples of lapen, and he found that lapen contained more than 1% of methanol. There was 2 kind of samples, green sample with melon flavour contained ethanol 2,87% and methanol 11,53%. Red sample with strawberry flavour contained ethanol 3,21% and methanol 12,64%. NA-DFC has decided that methanol level can be tolerated on food and beverage is 0,1%.

## Material and Methods

All patients admitted for methanol poisoning in October - December 2009 were included. Demographic data, sources and amount of methanol, clinical features, management, and outcomes were collected from the medical register.

## Results

### Case 1

A male, 28 years old, drunk three glasses of lapen about 1 week before he went to hospital. After that, when he woke up in the morning, his vision of the both eyes became blurred but no redness, no tearing, no painfull, no headache, and no vomit. One week afterwards, his vision of the both eyes became worse. His father took him to ophthalmologist. He had alcoholic history about 10 years. At his first time he came, his vision was no light perception (NLP) for both eyes. Ocular examination reveals pupillary dilatation, loss of pupillary reflexes, hyperemia and edema of the optic disk, and retinal hemorrhage at superior optic disc (**Figure 1a and 1b**). Results of the neurologic examination was normal. Laboratory results was all within normal limits except HDL decreased, SGOT increased, and SGPT increased. Abdominal USG result was fatty liver suspect.

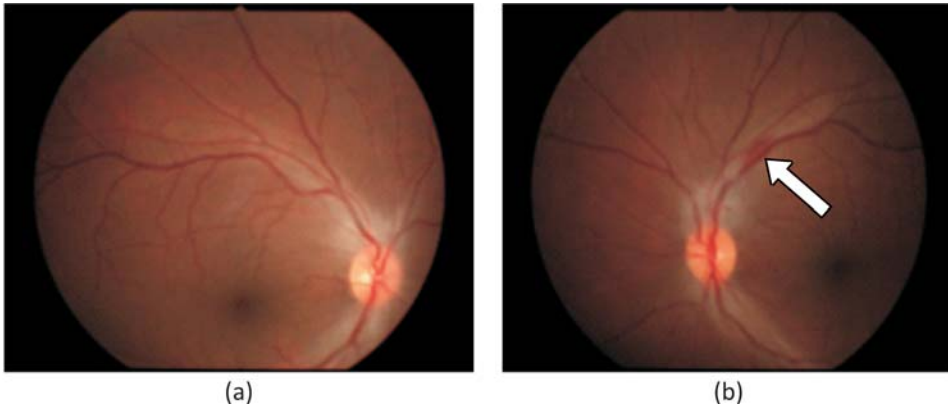


Figure 1. Fundus photograph (OD) that there was hyperemia and edema of the optic disc which taken at first visit (October 7<sup>th</sup>, 2009): (a) (b) retinal hemorrhage at superior optic disc (arrow).

He hospitalized for a week. He was treated 48 mg methyl prednisolone orally for 2 week and neurobion 5000 (thiamine HCl-100 mg, pyridoxine HCl-100 mg, cyanocobalamin 5000 mcg) injection for 1 week. Afterwards, the methyl prednisolone was tapered slowly and neurobion injection was changed in oral tablet daily. After 1 month, his vision of the both eyes still the same. From the sample of his drink, we found methanol 4,38% and ethanol 4,91%. Because his vision didn't improve, he became frustrated and never controlled again.

## Case 2

A male, 46 years old, drunk one glass of lapen about 4 days before he went to hospital. His vision of the both eyes became blurred but no redness, no tearing, no painfull, no headache, and no vomit. One day afterwards, his vision of the both eyes became worse. His son took him to ophthalmologist. He had alcoholic history about 20 years. At his first time he came, his vision was no light perception (NLP) for both eyes. Ocular examination reveals pupillary dilatation, loss of pupillary reflexes, hyperemia and edema of the optic disk. Results of the neurologic examination were normal. Laboratory results were all within normal limits except SGOT and SGPT increased. Abdominal USG result was cirrhosis hepar. He hospitalized for a week. He was treated 48 mg methyl prednisolone orally for 2 week and neurobion 5000 (thiamine HCl-100 mg pyridoxine HCl-100 mg cyanocobalamin-5000 mcg) injection for 1 week. Afterwards, the

methyl prednisolone was tapered slowly and neurobion injection was changed in oral tablet daily. After 1 month, his vision of the both eyes still the same. From the sample of his drink, we found methanol 12.41% and ethanol 3,74%. Unfortunately, after 1 month treatment, he didn't controlled again.

### Case 3

A male, 21 years old, drunk more than 3 glasses of combination of Vodka, lapen, Kratingdaeng, and beer. The visual acuity were 3/60 for the right eye and hand movement (HM) for the left eye. On admission, physical and neurological examination were normal.

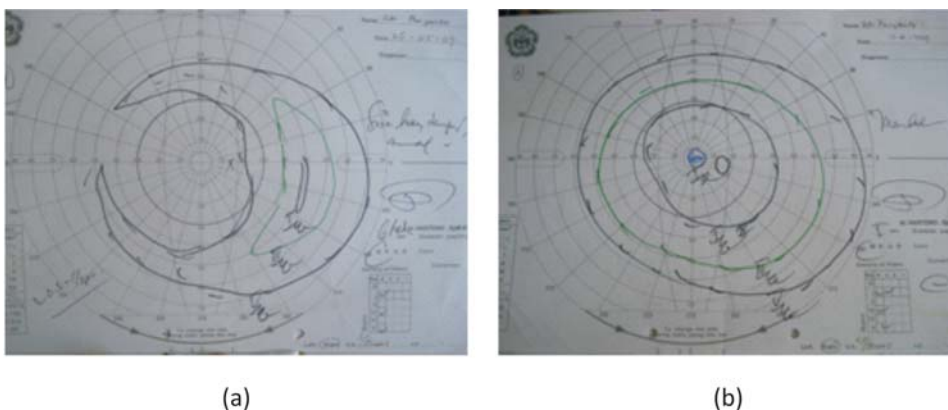


Figure 2. Visual field examination with Goldman perimetry: (a) taken at first visit. The result was minimal temporal remnant for the right eye and could not be performed for the left eye, (b) taken after 1 month treatment. The result was improved.

Ocular examination was normal except for mild dilatation of the pupils which reacted sluggishly to light. Relative afferent pupillary defect was not detected. Funduscopy examination were pale optic discs for the both eyes. Visual field examination was performed at first visit. The result was minimal temporal remnant for the right eye and could not be performed for the left eye (**Figure 2a**). Blood laboratory tests were normal with no evidence of metabolic acidemia. The conventional treatment with bicarbonate was longer not appropriate because the patient's acidbase balance was normal. Furthermore, the treatments with ethanol or haemodialysis were too late to be effective. Medical therapy was initiated including methyl prednisolone 48 mg/day orally and an intramuscular injection of neurobion 5000 (thiamine HCl-100 mg, pyridoxine HCl-100 mg,

cyanocobalamin 5000 mcg) daily. One month after initiating the treatment, visual acuity showed evidence of significant improvement in both eyes. His vision had improved became 3/60 for the right eye and 2,5/60 for the left eye (**Figure 2b**). The visual fields of the both eyes also had improved. Unfortunately, we didn't have the sample of his drink.

## Discussion

Methanol is toxic alcohol that may be ingested accidentally or consumed as ethanol substitutes. Like ethanol, methanol cause intoxication and are metabolized by alcohol dehydrogenase (ADH), a process that creates toxic metabolites. Methanol produces the most severe and life-threatening poisoning (Jacobsen, 1986).

Methanol has been recognized as a human visual neurotoxin for more than a century, and the clinical features of acute human methanol toxicity have been extensively documented. Toxic exposure to methanol typically results in an initial transient central nervous system depression, followed by an asymptomatic latent period lasting 12 to 24 hours. This latent period is then followed by the development of formic acidemia, uncompensated metabolic acidosis, visual toxicity, coma, and in extreme cases, death. Visual disturbances generally develop between 18 and 48 hours after methanol ingestion and range from mild photophobia and misty or blurred vision to markedly reduced visual acuity and complete blindness. Susceptibility among persons to the acute effects of methanol is highly variable, and the minimum lethal dose is considered to be between 300 mg/kg and 1 g/kg. The minimum dose causing permanent visual defects is unknown, although blindness has been reported after ingestion of as little as 4 ml of methanol (Jacobsen, 1986; Hovda *et al.*, 2005).

Its metabolites causes ocular toxicity. The clinical presentation of methanol intoxication can vary greatly from patient to patient. Visual loss is dependent on the initial dose of methanol ingested and on the interval between ingestion and start of therapy, but the latter is more critical for outcome. Visual disturbances, described as "walking in a snowstorm," are common. Ocular examination reveals pupillary dilatation and loss of pupillary reflexes. Fundus findings in cases of acute methanol poisoning vary from peripapillary edema, hyperemia of optic disc and venous engorgement, to pallor of optic disc, attenuation and sheathing of vessels depending upon the time of presentation after methanol consumption (Jacobsen, 1986).

Rapid recognition and treatment of toxic alcohol poisonings is crucial to reduce the occurrence of morbidity and mortality. The key to diagnosis is a high index of suspicion and a thorough history in patients who appear drunk or who have unexplained acid–base abnormalities. Features such as hyperpnea (compensation for metabolic acidosis), visual complaints, pupillary dilation and a latent period between inebriation and more severe symptoms are suggestive of methanol poisoning (Jacobsen, 1986; Hovda *et al.*, 2005).

### **Pathophysiology**

The degree of toxicity correlates with the amount of methanol ingested, but not with presenting methanol levels. Latency between ingestion and toxicity occurs because of the time required to convert methanol to toxic metabolites. The toxic effects become apparent when alcohol dehydrogenase (ADH) has metabolized methanol to formaldehyde. Formaldehyde is highly toxic but is rapidly degraded by aldehyde dehydrogenase and other nonspecific enzymes to formic acid, which is responsible for the metabolic acidosis and visual toxicity observed in human methanol poisoning. Further metabolism of formic acid to carbon dioxide is dependent on folate. Visual changes with methanol poisoning are due to microtubule and mitochondrial destruction in the retrolaminar optic nerve (Hovda *et al.*, 2005; Plaziac *et al.*, 2003). Formate has been hypothesized to contain methanol that its level is more than 1%. Methanol by itself has low toxicity, but to produce retinal and optic nerve toxicity by disrupting mitochondrial energy production. In vitro studies have shown that formate inhibits the activity of cytochrome oxidase, the terminal electron acceptor of the mitochondrial electron transport chain involved in adenosine triphosphate (ATP) synthesis. Permanent visual damage in methanol-intoxicated humans and nonhuman primates has been associated with prolonged exposures (usually longer than 24 hours) to blood formate concentrations in excess of 7 mM. However, very little information is available on the potential for recovery of retinal function after toxic exposure to methanol-derived formate (Treichel *et al.*, 2003; Nozha *et al.*, 2007; Marina *et al.*, 2001).

## Treatment

The rationale for using steroids in methanol toxic neuropathy was based on the clinical experience with this drug being effective in other forms of optic neuropathies. The potential therapeutic effect of steroids on methanol optic neuropathy might be a reduction in the oedema of the nerve sheaths caused by the histotoxic anoxia as suggested by Sharpe *et al.*, (1982).

The common element in toxic optic neuropathy appears to be the disruption of the mechanisms participating in the correction of the oxidative stress. Alcohol is responsible for the disruption of anti-oxidant mechanisms. The concentration or availability of some anti-oxidants play a protective role against the development of optic neuropathy despite exposure to toxin. Because of that, B-group vitamins are useful for decreasing risk of neuropathy (Arnaud *et al.*, 2001; Orssaud *et al.*, 2007).

## Conclusions

Lapen is Yogyakarta home made beverage which contains with methanol. Methanol is toxic liquid that cause toxic optic neuropathy. Blindness is the most common symptom and permanent. Acute methanol poisoning is a potentially fatal public health problem in developing countries. For this reason, public education about the consequences of methanol consumption and legislative control should be emphasized.

## References

- Arnaud J, Fleites-Mestre P, Chassagne M, Verdura T, Garcia J, Hernandez-Fernandez T, *et al.*, 2001, Vitamin B intake and status in healthy Havanan men, 2 years after the Cuban neuropathy epidemic, *Br J Nutr*; 85(6):741-8
- Hovda KE, Urdal P, Jacobsen D., 2003, Increased serum formate in the diagnosis of methanol poisoning, *J Anal Toxicol*; 29:586–588.
- Jacobsen D., 1986, Methanol and ethylene glycol poisonings: mechanism of toxicity, clinical course: Diagnosis and treatment, *Med Toxicol*; 1: 309–334.
- Marina T. Seme, Phyllis S, Jay N, Janis T. Eells, and Michele M. Henry., 2001, Differential Recovery of Retinal Function after Mitochondrial Inhibition by Methanol Intoxication, *Invest Ophthalmol Vis Sci.*; 42:834–841.
- Nozha B, Youssef B, Nour A., 2007, Methanol poisoning in Tunisia: Report of 16 cases. *Clinical Toxicology*; 45, 717–720

Orssaud C, Roche O, Dufier JL., 2007, Nutritional optic neuropathies, *Journal of the Neurological Sciences* 262: 158-164

Plaziac C, Lachapelle P, Casanova C., 2003, Effects of methanol on the retinol function of juvenile rats. *Neuro Toxicol.*; 24:255–260.

Sharpe JA, Hostovsky M, Bilbao JM, Rewcastle NB., 1982, Methanol optic neuropathy: a histological study. *Neurology*; 32: 1093–100.

Treichel J, Henry MM, Skumatz CM, Eells JT, Burke JM., 2003, Formate, the toxic metabolite of methanol, in cultured ocular cells, *Neuro Toxicol.*; 24:825–834.