

Comparison of the effect of guava leaf extract (*Psidium guajava L.*) with polyvinylpyrrolidone-sodium hyaluronate on the number fibroblasts (study on white rats [*Rattus norvegicus*])

Rachmi Fanani Hakim*, Fakhrurrazi*, Fatimah Sahara Zamzami*

* Fakultas Kedokteran Gigi Universitas Syiah Kuala

Correspondence: rachmifananihakim@usk.ac.id

Received 11 February 2023; 1st revision 10 May 2023; 2nd revision 10 July 2023; Accepted 11 July 2023;
Published online 31 July 2023

Keywords:

Wound healing; guava leaf extract;
polyvinylpyrrolidone-sodium hyaluronate gel;

ABSTRACT

Background : Wound healing is a cellular and complex process that aims to restore the integrity of tissue damaged by injury. The phases that occur in the wound healing process are inflammation, proliferation, and maturation (remodeling). One of the final results of wound healing is fibroblasts proliferation. Fibroblasts have the ability to synthesize collagen fibers that will cover the injured area. Natural medicinal plants that have the potential to accelerate wound healing are guava (*Psidium guajava L.*) leaves which contain flavonoids, tannins, saponins, and alkaloids. Polyvinylpyrrolidone-sodium hyaluronate gel is one of the wound treatment products on the market and can help the wound healing process

Method: This research method was an experimental laboratory using 10 white rat samples which were divided into two groups and given injury to the mandibular anterior gingiva. Both treatment groups were applied topically in the morning and evening for 14 days, then the tissue was observed histologically.

Results: Observation of the number of fibroblasts in the treatment group applied to guava leaf extract gel had a mean of 28 ± 11 while the treatment group applied Polyvinylpyrrolidone-sodium hyaluronate gel was 10 ± 4 . The unpaired t test (Independent T-Test) showed a significance value of 0.000 ($p < 0.05$)

Conclusion: A significant difference in a comparative study of the effect of guava leaf extract with polyvinylpyrrolidone-sodium hyaluronate on the number of fibroblasts in gingival wound healing of Wistar rats.

Copyright ©2022 National Research and Innovation Agency. This is an open access article under the CC BY-SA license (<https://creativecommons.org/licenses/by-sa/4.0/>).

doi: <http://dx.doi.org/10.30659/odj.10.1.61-68>

2460-4119 / 2354-5992 ©2022 National Research and Innovation Agency

This is an open access article under the CC BY-SA license (<https://creativecommons.org/licenses/by-sa/4.0/>)

Odonto : Dental Journal accredited as Sinta 2 Journal (<https://sinta.kemdikbud.go.id/journals/profile/3200>)

How to Cite: Hakim *et al.* Comparison of the effect of guava (*psidium guajava l.*) Leaf extract x with polyvinylpyrrolidone-sodium hyaluronate on the number fibroblasts (study on white rats [*rattus norvegicus*]).

Odonto: Dental Journal, v.10, n.1, p. 61-68, July 2023.

INTRODUCTION

Wounds are defined as damage or loss of continuity in the skin or body tissues that can cause interference with the anatomical structure of the body.¹ Wounds can be caused by several things such as post-surgery, trauma, contact with heat sources, chemicals, and accidents.² Injuries that occur in the oral tissue one of which in the gingiva can occur due to surgery on the oral cavity.³ Wound healing is a cellular and complex process that aims to restore the integrity of tissue damaged by injury and has several phases that are interrelated to one another. Phases that occur in the process of wound healing are the inflammatory phase, the proliferation phase, and the maturation phase (remodelling).⁴ In these phases there will be changes in components that can be observed microscopically such as leukocytes, fibroblasts, macrophages, collagen fibers and neurovascularization.⁵ One determination of the end result of wound healing is fibroblast proliferation. Wound closure occurs because of collagen produced by fibroblasts, and the process of re-epithelialization in wound closure is the effect of the presence of fibroblasts.⁶ One of the plants that has medicinal properties and is known by the public is guava (*Psidium guajava* Linn.). According to Soedibyo (1998), all parts of guava plants can be utilized and have properties including their leaves.⁷ Guava leaf plants can be used as a wound healing because it has anti-inflammatory, hemostatic, and astringent effects (cit. Soedibyo, 1998).^{7,8} There are some chemical contents in guava leaves that can help wound healing are tannins, flavonoids, alkaloids, and saponin.⁹ According to research Fernandes et al. (2010), clinically and histologically, guava leaf extract given in rat wounds can heal faster than the group given corticosteroid drugs, so that it can be used as phytotherapy which can contribute to tissue recovery in wounds.¹⁰ Besides

medicinal plants, polyvinylpyrrolidone-sodium hyaluronate gel can also be used as an alternative for wound healing, this drug has a blend of chemicals and natural ingredients on the market.¹¹ Based on studies conducted by Burchel et al. (2008), wound healing in the oral cavity after surgery can be done by administering polyvinylpyrrolidone-sodium hyaluronate gel.¹²

Polyvinylpyrrolidone-sodium hyaluronate gel is one of the ready-made drug preparations that works topically.¹³ The content contained in polyvinylpyrrolidone-sodium hyaluronate gel is aloe vera, sodium hyaluronate, glycolic acid, and polyvinylpyrrolidone (PVP).¹² According to Kapoor et al. (2011), Sodium hyaluronate has a function of tissue healing, activation of the inflammatory response, proliferation, migration, and angiogenesis.¹⁴ Benefits of glycyrrhetic acid contained in polyvinylpyrrolidone-sodium hyaluronate gel can be an antioxidant and anti-inflammatory agent that has the potential to accelerate the wound healing process.^{12,13}

Research on the comparison of the effect of guava leaf extract with polyvinylpyrrolidone-sodium hyaluronate gel on wound healing has been conducted by Hidayatika (2018). The results of the study showed that there were significant differences in the rate of wound healing which was marked by starting to reduce overall wound size in both groups on the 3rd day and 4th day, through research for 16 days until the wound healed. Based on this, the authors would like to investigate further the comparison of the effect of the extract of guava with polyvinylpyrrolidone-sodium hyaluronate on the number of fibroblasts in gingival wound healing of Wistar rats.

RESEARCH METHOD

This research is an experimental laboratory research and uses a posttest-only control group design¹⁵

Samples Preparation

This study used 10 male Wistar rats (*Rattus norvegicus*), ages 8-12 weeks, and weighed 200-300 grams obtained from the Faculty of Veterinary Medicine, Syiah Kuala University.¹⁵ Rats were divided into 2 groups with each group totaling 5 rats.

Making Guava Leaf Extract

The sample used was guava leaf which was taken using a random sampling technique. Samples that have been collected are cleaned with running water 2 times. Furthermore, guava leaves are dried by aerated without direct sunlight until they are brittle. The next stage the sample is blended to a fine powder, then weighed on the sample using a 500g sitting scale for extraction.⁷

Guava leaf powder was then dissolved into 96% ethanol for 5 days. Then proceed with the process of remaseration with 96% ethanol for 3 days. The results of this maceration process are then filtered using filter paper and the filtrate is taken. The filtrate obtained was then evaporated using a rotary evaporator, to obtain a thick extract of guava leaves .^{17,18}

Preparation of Guava Leaf Extract Gel

The thick extract of guava leaves is processed into a gel preparation by dissolving with heated aquadest and then put into a mortar and added with Na-CMC, waiting until it expands then stirring for about 15 minutes until homogeneous and precipitated mucus forms down. The next process is to add propylene glycol, nipagin, glycerin, tri-ethanol-amine, and stir until homogeneous.¹⁷

Guava leaf extract put on another mortar and then dissolved using partially heated aquadest at 50°C and added Na-CMC that has been formed,

stirred until homogeneous until gel mass is formed. The formed gel is stored in a vial bottle and left at room temperature overnight.^{17,19}

Animal Preparation

Samples of 14 male rats were obtained from animal cages of the Faculty of Veterinary Medicine, Syiah Kuala University, Banda Aceh, aged 8-12 weeks, average weight 200-300 g with healthy condition, without defects, white-haired, smooth, active moves, and good nutritional status.^{19,20}

Making Incision Wounds in Rat Gingiva

Incision wounds are made in the gingival area of the lower labial area of both mandibular anterior teeth. Before injury the rat must be anesthetized using a single intramuscular injection of ketamine hydrochloride 10mg/kg and xylazine hydrochloride 1-2mg/kg. The injury was made using scalpel and blade no. 11 on the labial gingiva under the anterior teeth of the mandible along the 5mm with the depth of the wound until reach the alveolar bone.

Application of Guava Leaf Extract Gels and Polyvinylpyrrolidone-sodium Hyaluronate Gel on Gingival Wounds

Wistar rats as many as 14 males were divided into two treatment groups namely, one treatment group was first applied to guava leaf extract gel topically and the second treatment group was applied polyvinylpyrrolidone-sodium hyaluronate gel. Both treatment groups were applied topically to the injured area evenly by using a 1 cc syringe as much as 0.1 ml each day twice in the morning and evening for 14 days.^{7,21}

Observation of Histological Preparations

After the treatment period ended, the rats were then deuthanated. The next process is tissue cutting in the mandible of the rats which is cut with a thickness of 2-3 mm and followed by a fixation

process that is inserting tissue into a 10% formalin neutral buffer solution for 24 hours to maintain the cell structure.³ The next process the tissue is dehydrated (withdrawal of water from the tissues) or soaking in alcohol, the dehydration stage begins with 70% alcohol for about 15 minutes, 80% for 1 hour, 95% for 2 hours, 96% for 1 hour, and 100% alcohol for 3 hours. After that, soaking in Xylol solution (clearing or purification) three times in different containers with a span of 1 hour, 2 hours, and the last immersion with a time of 2 hours. Then the tissue was infiltrated using paraffin fluid at a temperature of 57°-59°C for 1.5 hours.²² The next process was tissue implantation in a paraffin block and each paraffin block was cut as thick as 5 µm using a microtome.^{3,23} Staining the preparation using the hematoxylin eosin method (HE) with three stages, namely coloring, dehydration, and clarification.³

Data analysis

Data analysis was performed using SPSS 20 and hypothesis testing was performed with an unpaired T-test if the data distribution was normal with significant ($p < 0.05$).

RESULTS

Observation Results on Histology Preparations

The results of this study indicate the average number of fibroblast cells in rat. The first treatment group applied guava leaf extract gel had an average number of fibroblasts of 28 ± 11 while the second treatment group applied polyvinylpyrrolidone-sodium hyaluronate gel had an average number of fibroblasts of 10 ± 4 (Table 1).

Table 1. The Average Results of Fibroblasts Number

Variable	Groups	n	Mean±SD
Number of Fibroblasts	Treatment 1	5	28 ± 11
	Treatment 2	5	10 ± 4

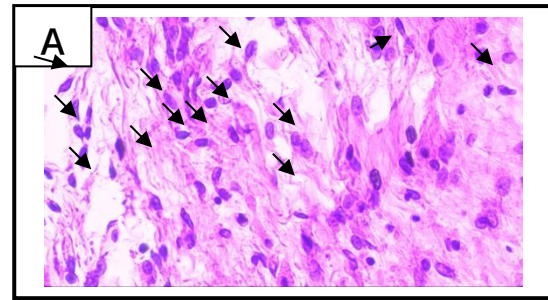


Figure 1. Figure of Fibroblast in the Treatment Group Applied with Extract Gel Guava Leaves (→ = Fibroblast cells)

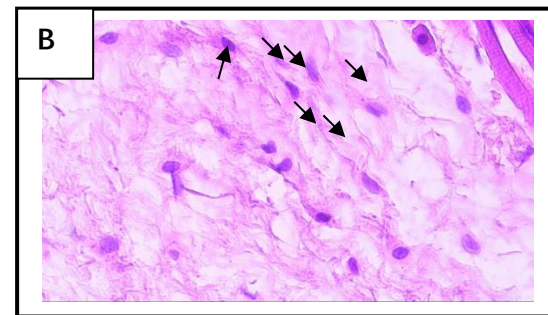


Figure 2. Figure of Fibroblast Cells in the Treatment Group which was applied polyvinylpyrrolidone-sodium hyaluronate gel as Seen from a microscopic photograph with magnification (400x) (→ = Fibroblast cells)

Data analysis

Before performing the unpaired t test, used test data normality using the Shapiro-Wilk test because the sample size in this study is less than 50 samples.

Table 2. Data Normality Test Results

Variable	Groups	Saphiro-Wilk	p
Number of Fibroblasts	Treatment 1	5	0,547
	Treatment 2	5	0,052

In table 2. the data normality test results show the normal distribution of data in both treatment groups with the first treatment group showing the value of $p = 0.547$ and the second treatment group showing the value of $p = 0.052$. Requirements for normal data distribution are $p > 0.005$, therefore hypothesis testing can be done using an unpaired t test.

Table 3. Independent T Test Statistical Test Results

Variable	Groups	n	Sig.(2-tailed)
Number of Fibroblasts	Treatment 1	5	,000
	Treatment 2	5	,000

Table 3. shows the results of statistical tests using the unpaired t-test (Independent T Test) which produces a significance value of 0.000 ($p < 0.05$), it can be concluded that there is a significant difference between the one treatment group that was applied to guava leaf extract gel (*Psidium guajava* Linn.) with the second treatment group that was applied polyvinylpyrrolidone-sodium hyaluronate gel.

DISCUSSION

This research was conducted to see the comparison of guava leaf extract gel (*Psidium guajava* Linn.) with polyvinylpyrrolidone-sodium hyaluronate gel against the number of fibroblasts conducted in rats . This study used 14 white rats by making incision wounds in the gingiva of rats with a 5 mm long wound with depth reaching the alveolar bone. In this study, the place of injury, the size of the wound, the condition and environment of the cage were carried out uniformly for all treatment groups.

In this study, guava leaf (*Psidium guajava* Linn.) extract gel in 5% concentration. According to the research of Desiyana et al (2016), a gel with a concentration of 5% has a better dispersion power than a gel with a concentration of 7% so that it can affect the release of active substances, and a concentration of 5% is proven to accelerate wound healing by faster scab formation in mice wounds than concentration of 7% .¹⁷ Based on the research of Aponno et al (2012), wound healing in rabbits given guava leaf extract gel with a concentration of

5% recovered faster than guava leaf extract concentration of 7% .²¹

Guava leaf extract made into a gel preparations using a gel base propylene glycol, Na-CMC, glycerin, nipagin, and tri-ethanol-amine (TEA). Na-CMC is one of the gelling agents that has the best adhesion, provides a moist on the wound, and high spreadability so that it can spread easily over the skin.²⁴ Glycerin can be used as an emollient and humectant which has benefits as an anti-inflammatory agent. Propylene glycol has benefits for preventing evaporation, disinfectants, antimicrobial agents, and humectants. Gel preparations have several advantages including the ability to spread and release drugs that are good, stable, fast absorption and have a cold effect.

This study used 10 white rats (*Rattus norvegicus*) which were divided into two treatment groups, namely the first treatment group was given guava leaf extract gel (*Psidium guajava* Linn.) And the second treatment group was given Polyvinylpyrrolidone-sodium hyaluronate gel, each group consisting from five mice. Rats treated with guava leaf extract gel and polyvinylpyrrolidone-sodium hyaluronate gel topically twice a day twice a day in the morning and evening using 0.1 cc syringes as much as 0.1 ml with a difference of 12 hours for 14 days treatment.^{25,26}

The administration of guava leaf extract gel and polyvinylpyrrolidone-sodium hyaluronate gel to white rats was given for 14 days due to the ongoing proliferation phase in wound healing marked by an increase in the number of fibroblast cells. After the treatment period ended for 14 days, all rats were euthanized first using ether solution before making histological preparations. Staining in histology preparations using HE and observing the number of fibroblast cells in the wound area using a

microscope with 5 field of view using 400x magnification and then calculating the average.²⁶

The results of this study were obtained by calculating the average number of fibroblast observed from the two treatment groups, the first treatment group had an average cell count of 28 ± 11 and the second treatment group had an average of 10 ± 4 . From the results obtained there are significant differences between the first and second treatment groups. The results of this study are consistent with research conducted by Wisesa (2017) about the difference in the effect of giving guava leaf extract with povidone iodine 10% on the number of fibroblasts and collagen thickness after the removal of marmot's teeth histopathologically which states that the number of fibroblast cells is higher in the first group were given guava leaf extract and povidone iodine 10%, namely 176 ± 45 , the second group who were given guava leaf extract totaled 136 ± 50 , while in the third group only smeared with povidone iodine 10% of the number of fibroblast cells is 93 ± 22.27 . Research conducted by Wisesa shows a higher number of fibroblasts with guava leaf extract and 10% povidone iodine with greater depth and size of the wound and the addition of wound Povidone iodine 10% can affect the number of fibroblasts, speed and effect activity of wound healing. The results of this study are also in accordance with the opinion of Fernandes et al. (2010), clinically and histologically, guava leaf extract given in rat wounds can heal faster than the group given corticosteroid drugs, so that it can be used as phytotherapy which can contribute to tissue recovery in wounds.¹⁰

Research conducted by Rachmi et al (2019), states that *Carica papaya* extract can more quickly heal incision wounds and increase the number of fibroblasts in mice gingiva with a group given *Carica papaya* extract with a concentration of 75% than the control group with wound lengths that

seem to start to close on day 3 and close by perfect on the 14th day and an increase in fibroblast cells, a perfect epithelial layer, and wound contraction.¹⁵ Wound healing can be achieved by giving medicinal plants that contain material and nutrients to help speed up the wound healing process that is usually used in topical form.²⁸ One of the plants that has medicinal properties and is known by the public is guava.⁷ According Hidayatika research results (2018), showed that there was a significant difference in wound healing rate which was characterized by faster closing of the wound completely applied to guava leaf extract gel than the wound that was applied polyvinylpyrrolidone-sodium hyaluronate gel.²⁹

According to the results research Kaneria, et al (2011) guava leaves have compounds that can help wound healing such as saponins, alkaloids, flavonoids, and tannins.^{9,30} The contents contained in tannin are useful as astringents or the ability to stop bleeding, regenerate new tissue, and accelerate healing a wound and inflammation of the mucous membrane.³¹ Flavonoids also function as anti-inflammatory or anti-inflammatory which can prevent the occurrence of pain and stiffness.³² Alkaloid compounds have antimicrobial and antibacterial properties.³³ The saponin compounds have antimicrobial effects and help the formation of collagen.³⁴ Alkaloid compounds have oral antimicrobial and antibacterial properties.³³ The saponin compounds have antimicrobial effects and help the formation of collagen. Containing polyvinylpyrrolidone and sodium hyaluronate function as a protective layer so that it can reduce tissue irritation and pain.^{13,51} Polyvinylpyrrolidone-sodium hyaluronate gel has antibacterial, anti-inflammatory properties, accelerates cell proliferation, and cell migration in wound healing.^{11,12,35}

Statistical test results showed that there was a significant difference between the first treatment group that was applied to guava leaf extract gel with the second treatment group which was applied polyvinylpyrrolidone-sodium hyaluronate gel with a significant value of 0.000 (<0.05). Based on this analysis it can be concluded that there is a comparison of the effect of guava leaf extract gel with polyvinylpyrrolidone-sodium hyaluronate gel on the number of gingival fibroblasts of rats gingival wound healing.

CONCLUSION

Based on this research, it can be concluded that there is a significant difference in a comparative study of the effect of guava leaf extract (*Psidium guajava* Linn.) With Polyvinylpyrrolidone-sodium hyaluronate on the number of fibroblasts (Study on White Rats [*Rattus norvegicus*])

REFERENCES

1. Politis. C, Schoenaers J, Jacobs R and. Agbaje. J. O. Wound Healing Problems in the Mouth. *Frontiers in Physiology*. 2016; 7: 507 .
2. Jeschke MG, van Baar ME, Choudhry MA, Chung KK, Gibran NS, Logsetty S. Burn injury. *Nat Rev Dis Primers*. 2020; 6(1):11.
3. Kartikaningtyas TA, Prayitno, Lastianny. Pengaruh aplikasi gel ekstrak kulit Citrus Sinesis terhadap Epitelisasi ada penyembuhan luka gingiva Tikus Sprague Dawley. *Majalah Kedokteran Gigi Indonesia* 2015;1(1):86-87.
4. Afra I. Toma, Julia M. Fuller, Nick J. Willett, Steven L. Goudy. Oral wound healing models and emerging regenerative therapies, *Translational Research*. 2021; 236: 17-34.
5. Nanci A. Ten Cate's Oral Histology: development, structure, and function. 9th ed. Canada:Elsevier Health Sciences. 2017.
6. Sumbayak ME. Fibroblas: Struktur dan Peranannya dalam Penyembuhan Luka. *Jurnal Kedokteran Meditek Ukrida* 2016; 21(57):1-2.
7. Oktiarni D, Manaf S, Suripno. Pengujian Ekstrak Daun Jambu Biji (*Psidium guajava* Linn.) Terhadap Penyembuhan Luka Bakar Pada Mencit (*Mus musculus*). *Jurnal Gradien* 2012; 8(1):752-755.
8. Ekom ES, Tamokou DJ. Methanol Leaves Extract of *Psidium guajava* Liin. Exhibited Antibacterial and Wound Healing Activities. *International Journal Current Microbiology Applied Sciences* 2018;7(7):4008-4023.
9. Kaneria, M., Chanda.S. Phytochemical and Pharmacognostic Evaluation of Leaves of *Psidium guajava* Linn. (Myrtaceae). *Pharma Journal* 2011; 3 (10): 23-6.
10. Fernandes KPS, Bussadori SK, Marques MM, Sumie N, Wadt Y, Bach E, Martins DM. Healing and cytotoxic effects of *Psidium guajava* (Myrtaceae) leaf extracts. *Brazilian Journal of Oral Sciences* 2010;9(4):449-454.
11. Honestdoc. Aloclair : Kegunaan, dosis, dan efek samping. 13 Juni 2019. <https://www.honestdocs.id/alocclair>.
12. Buchsel CP, Murphy JM. Polyvinylpyrrolidone-sodium hyaluronate gel (Gelclair®): a bioadherent oral gel for the treatment of oral mucositis and other painful oral lesions. *Expert Opinion on Drug Metabolism and Toxicology*. 2008;4(1):1449-1454.
13. Jornet, Lopez, Alonso. Clinical Evaluation of Polyninylpyrrolidone-sodium hyaluronate gel and 0.2% Chlorhexidine gel for pain after oral mucosa biopsy: A preliminary study. *Journal of Oral Maxillofacial Surgery*. 2010; 68(9) : 2159 - 63
14. Kapoor, Sachdeva. Topical Hyaluronic Acid In The Management Of Oral Ulcers. *Indian Journal of Dermatology* 2011;56(3) : 300-302.
15. Hakim R F, Fakhurrrazi, Dinni. Effect of *Carica papaya* Extract toward Incised Wound Healing Process in Mice (*Mus musculus*) Clinically and Histologically. *Hindawi Evidence-Based Complementary and Alternative Medicine* 2019;2019 (1): 1-5.
16. Tama C, Dewi EN, Ibrahim R. The Effect of *Gracilaria verrucosa* Extract Feeding to the Blood Glucose Content of White Rats (*Rattus norvegicus*). *JSaintek Perikan*. 2012;8(1):2.
17. Desiyana L.S, Husni M, A & Suprianti. Uji Efektivitas Sediaan Gel Fraksi Asetat Daun Jambu Biji (*Psidium Guajava* Linn) Terhadap Penyembuhan Luka Terbuka Ada Mencit. *Jurnal Natural* 2016;16(2);23-32.
18. Anggraeni HD, Liviawaty E, Pratama IR, Rostini I. Pengaruh Konsentrasi Ekstrak Daun Jambu Biji Terhadap Masa Simpan Filet Patin Berdasarkan Jumlah Mikroba. *Jurnal Perikanan dan Kelautan* 2017;8(2):146-147.
19. Tambunan S, Asni E, Zulkifl , Ismawati. Histopatologi Aorta Torasika Tikus Putih (*Rattus Norvegicus* Strain Wistar) Jantan Setelah Pemberian Diet Aterogenik Selama 12 Minggu. *Jurnal Online Mahasiswa Fakultas Kedokteran Universitas Riau* 2014;2(1):3.

20. World Health Organization. Research Guidelines For Evaluating The Safety And Efficacy Of Herbal Medicine. *Newyork:WHO Publication*.1993.p.37-41.
21. Aponno VJ, Yamlean P, Suppriati H. Uji Efektivitas Sediaan Gel Ekstrak Etanol Daun Jambu Biji (*Psidium Guajava Liin*) Terhadap Penyembuhan Luka Yang Terinfeksi Bakteri *Staphylococcus Aureus* Pada Kelinci (*Orytolagus Cuniculus*). *Pharmacon Unsrat* 2014;3(3):280-281.
22. Mulyono A, Ristiyanto, Soesanti N. Karakteristik Histopatologi Hepar Tikus Got (*Rattus norvegicus*) Infektif *Leptospira sp.* *Jurnal Vektora* 2009;1(2):84-90.
23. Pratiwi CH, Manan A. Teknik dasar histologi pada ikan gurami (*Osphronemus gouramy*). *Jurnal Ilmiah Perikanan dan Kelautan* 2015;7(2):153.
24. Shan WY, Wicaksono IA. Artikel Tinjauan : Formulasi Gel Ekstrak Kulit Manggis (*Garcinia mangostana*) dengan Variasi Konsentrasi Basis. *Farmaka* 2018;16(2):114.
25. Novitasari MIA, Indraswary E, Pratiwi R. Pengaruh Aplikasi Gel Ekstrak Membran Kulit Telur Bebek 10% Terhadap Kepadatan Serabut Kolagen Pada Proses Penyembuhan Luka Gingiva. *Odonto Dental Journal* 2017;4(1): 18.
26. Hazizah N. Pengaruh B-Chitosan Gladius Cumi-Cumi (*Loligo Sp.*) Terhadap Jumlah Fibroblas Gingiva Tikus Wistar (*Rattus Norvegicus*) Jantan Secara Histopatologis. Program Studi Kedokteran Gigi Fakultas Kedokteran Universitas Syiah Kuala Darussalam-Banda Aceh. 2013; Hal 24;26. *Skripsi*.
27. Wisesa SD. Kombinasi Pasta Ekstrak Daun Jambu Biji (*Psidium guajava linn.*) 5% dan Povidon Iodine 10% Efektif Meningkatkan Jumlah Fibroblas dan Ketebalan Kolagen Pasca Pencabutan Gigi Marmut (*Cavia cobaya*). Program Magister Studi Ilmu Biomedik Fakultas Kedokteran Universitas Udayana Denpasar. 2017; Hal 53-54. *Thesis*.
28. Sugiaman VK. Peningkatan penyembuhan luka di mukosa oral melalui pemberian *Aloe Vera* (Liin.) secara topikal. *Jurnal Kesehatan Masyarakat* 2011; 11(1):72-73.
29. Hidayatika D. Perbandingan Pengaruh Ekstrak Daun Jambu Biji (*Psidium guajava L.*) dengan *Polyvinylpyrrolidone-sodium hyaluronate gel* Terhadap Penyembuhan Luka (Studi pada Tikus Putih (*Rattus norvegicus*)). Program Studi Pendidikan Dokter Gigi Fakultas Kedokteran Gigi Universitas Syiah Kuala Darussalam-Banda Aceh. 2018; Hal 34. *Skripsi*.
30. Afifi R, Erlin E. Uji Anti Bakteri Ekstrak Daun Jambu Biji (*Psidium guajava L*) Terhadap Zona Hambat Bakteri Jerawat *Propionibacterium acnes* Secara In Vitro. *Jurnal Kesehatan Bakti Tunas Husada* 2017;17(2):321.
31. Kusumawardhani DA, Kalsum U, Rini SI. Pengaruh Sediaan Salep Ekstrak Daun Sirih (*Piper betle* Linn.) Terhadap Jumlah Fibroblas Luka Bakar Derajat IIA Pada Tikus Putih (*Rattus norvegicus*) Galur Wistar. *Majalah Kesehatan FKUB* 2015;2(1):18.
32. Ramadhani N, Sumiwi AS. Aktivitas Antiinflamasi Berbagai Tanaman Diduga Berasal dari Flavonoid. *Farmaka* 2016; 14(2):111-112.
33. Ningrum R, Purwanti Elly, Sukarsono. Identifikasi Senyawa Alkaloid dari Batang Karamunting (*Rhodomyrtus tomentosa*) sebagai bahan ajar biologi untuk kelas X. *Jurnal Pendidikan Biologi Indonesia* 2016; 2 (1):231-236.
34. Agustina E, Andiarna F, Lusiana N, Purnamasari R, Hadi IM. Identifikasi senyawa aktif dari ekstrak daun jambu air (*Syzygium aqueum*) dengan perbandingan beberapa pelarut pada metode maserasi. *The Journal of Tropical Biology* 2018; 2(2):109-110.
35. Nazir F, Azhari A, Anas E. Pengaruh Pemberian Gel Lidah Buaya (*Aloe Vera*) Terhadap Jarak Pinggir Luka Pada Tikus Wistar. *Jurnal Kesehatan Andalas* 2015; 4 (3): 832