

## THE EFFECT OF PERIODONTAL PACK WITH ADDITIONAL PLANTS OF IODINE (*JATROPHA MULTIFIDA L.*) POST CURETTAGE

Ade Ismail Abdul Kodir\*, Muhamat Muhtar S Abdurrohman\*\*, Talitha Novi Rahmaningrum\*\*\*

\* Departemen Periodonsia Fakultas Kedokteran Gigi Universitas Islam Sultan Agung

\*\*Departemen Biologi Oral Fakultas Kedokteran Gigi Universitas Islam Sultan Agung

\*\*\* Program Pendidikan Dokter Gigi Fakultas Kedokteran Gigi Universitas Islam Sultan Agung

Correspondence : [ade@unissula.ac.id](mailto:ade@unissula.ac.id)

### Keywords:

*Iodine Leaf Extract Gel;  
Periodontal Curettage;  
Wound Healing; Fibroblasts*

### ABSTRACT

**Background:** Curettage is an act of scraping the granulation tissue on the lateral gingival wall of the periodontal pocket. After curettage, a periodontal pack was applied to control bleeding and keep the wound area clean. The addition of iodine leaves as an alternative because it contains flavonoids that can help the wound healing process. This study aims to determine the effect of adding 10% iodine leaf extract gel on the curettage process.

**Method:** A true experimental laboratory study with a post-test only control group design on 20 wistar rats. The periodontal pack group and the periodontal pack group were added with 10% iodine leaf extract gel. Curettage healing was seen from the mean number of fibroblasts using One-Way Anova analysis.

**Result:** The study showed the mean number of fibroblasts on the 5th and 7th day periodontal pack groups were 35.20 and 49.60, while those in the periodontal pack group with the addition of iodine leaf extract gel on 5th and 7th days were 45.80 and 50.80, respectively. The One-Way Anova test showed  $p > 0.05$ , there was a significant difference in the mean number of fibroblasts between the study groups.

**Conclusion:** The conclusion is that there is an effect of giving 10% iodine leaf extract gel on the number of fibroblasts in the healing process of wistar rat curettage.

### INTRODUCTION

Periodontal disease is an inflammatory reaction that occurs due to bacteria in the supporting tissues of the teeth. The main cause is the bacteria *Aggregatibacter actinomycetemcomitans*, *Porphyromonas gingivalis* and *Prevotella intermedia*<sup>1</sup>. The characteristic of periodontal disease is the formation of pockets, namely the deepening of the gingival sulcus. The formation of this pocket occurs during inflammation of the connective tissue of the gingival sulcus. Degeneration of the

surrounding connective tissue occurs as a result of inflammatory cells and fluid exudates including the gingival fibers<sup>2</sup>.

The procedure for removing the cause of periodontal pockets is by closed curettage and open curettage. Curettage is the act of scraping the granulation tissue on the wall. Then an evaluation is carried out to check the results of the treatment. This advanced stage is carried out in a weekly or monthly period. At the time of evaluation, pocket depth and gingival

inflammation were measured, as well as plaque and calculus index<sup>3</sup>.

The application of dressings/periodontal packs is carried out in the operating area. In certain circumstances, the use of a periodontal pack has the advantages, among others, of protecting the wound and stability of wound healing. Periodontal packs can prevent bleeding, infection and reduce tooth sensitivity in the surgical area. There are several types of periodontal packs, eugenol dressings and non-eugenol dressings. In dental practice, eugenol dressings consisting of a base and a catalyst are widely used. The base composition is zinc oxide, oils, and lorcetamol, while the catalyst composition is fatty acids and chlorothymol. As the main ingredient is Zinc oxide, oils as plasticizer (bacteriostatic agent)<sup>5</sup>.

There are several herbs that can be used as wound healing drugs. Among them is the iodine tree (*Jatropha multifida* L.). Many uses of this plant, including the sap to treat swelling and new wounds. The stems have been studied to heal wounds and have an equivalent of 10% povidone iodine<sup>6</sup>. *Jatropha multifida* L. stems contain flavonoids. Flavonoids are antioxidants, compounds that protect cells against the effects of damage by reactive oxygen species<sup>7</sup>. Based on previous research, the stem of this plant contains flavonoids, alkaloids, saponins, and tannins. Antibiotics, there are saponins that can accelerate wound healing because it inhibits the growth of bacteria<sup>8</sup>.

This study aims to determine the effect of iodine plants. in wound healing after curettage.

Another objective is to determine the effect of the application of iodine plants. on the periodontal pack in increasing the number of fibroblasts in post-curettage wound healing.

## RESEARCH METHODS

This research is an in vivo experimental with a post test only with control design. The sample used in this study was 20 male wistar rats divided into 2 groups, namely control and treatment. Divided into 2 sub groups, consisting of 5 tails. In the control group, the first sub-control group consisted of 5 rats treated with curettage and given a periodontal pack then decapitation on day 5. The second control subgroup, mice were decapitated on the 7th day. In the treatment group, the first treatment subgroup was 5 rats which were treated with curettage and given a periodontal pack plus 10% iodine leaf extract gel (*Jatropha multifida* L.) then the rats were decapitated on the 5th day. The second treatment subgroup, mice were decapitated on the 7th day.

Tahap selanjutnya, dibuat preparat menggunakan metode mikroteknik jaringan. Pengamatan mikroskopis dilakukan untuk menghitung jumlah sel fibroblas dengan perbesaran 400 kali. Pengamatan dilakukan dalam lima lapang pandang kemudian jumlah dari seluruh hasil pengamatan dirata-rata.

## RESEARCH RESULT

The results of microscopic observations and histological counting of fibroblasts showed the average value of the number of fibroblasts in each group, namely:

Table 1. Data on the mean number of fibroblasts in the group

Group	Mean $\pm$ Std.Deviasi
Periodontal pack 5H	44,00 $\pm$ 2,915
Periodontal pack 7H	63,20 $\pm$ 2,280
GEDY 10% 5H	48,60 $\pm$ 1,817
GEDY 10% 7H	69,40 $\pm$ 2,702

Description: GEDY (Iodine Leaf Extract Gel)

Based on the table the mean value of the number of fibroblasts, it is known that the average on the fifth day of the periodontal pack group was 44.00  $\pm$  2.915, the seventh day of the periodontal pack was 63.20  $\pm$  2.280, the periodontal pack was

added with 10% iodine leaf extract gel. 5th day of 48.60  $\pm$  1.817 and the periodontal pack with the addition of 10% iodine leaf extract gel on the 7th day of 69.40  $\pm$  2.702

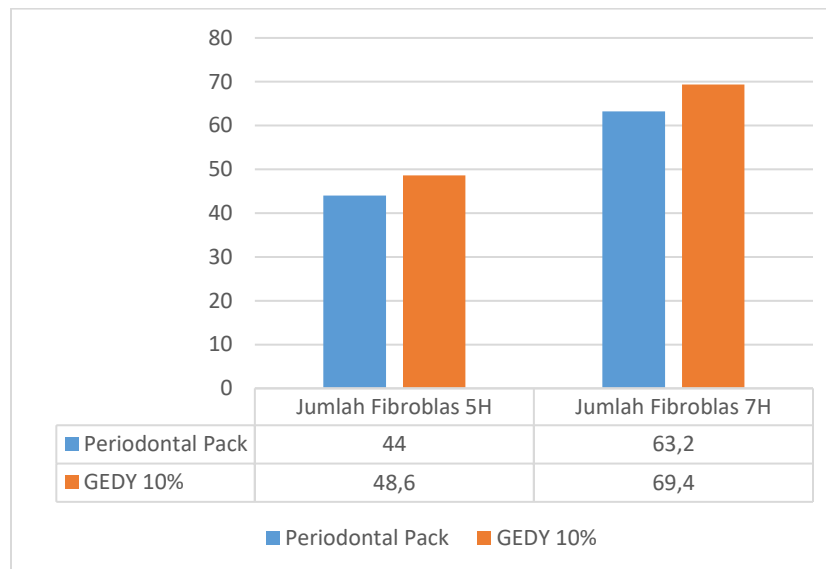


Figure 1. The average value of the number of fibroblasts in each group

The effect of 10% iodine leaf extract gel (*Jatropha multifida* L.) on wound healing after curettage in male wistar rats can be seen from the number of fibroblast cells from the results of statistical tests. The normality test of the data was carried out

using the Shapiro-Wilk method because the data samples in each group were less than 50 samples. The results of the normality test are as follows:

Table 2. Shapiro Wilk normality test results

Group		Sig	Desc
<i>Test of normality</i>	<i>Periodontal pack 5H</i>	0,585	Data is normally distributed
	<i>Periodontal pack 7H</i>	0,329	Data is normally distributed
	GEDY 10% 5H	0,826	Data is normally distributed
	GEDY 10% 7H	0,980	Data is normally distributed

Description: GEDY (Iodine Leaf Extract Gel)

Based on the results of the normality test using the Shapiro-Wilk, the data obtained were normally distributed ( $p > 0.05$ ) in all treatment

groups, then the homogeneity test was carried out with the following results:

Table 3. Homogeneity test results (*Levene test*)

Group	Sig	Desc
<i>Periodontal pack 5H</i>	0,499	Homogeneous Data
<i>Periodontal pack 7H</i>		
GEDY 10% 5H		
GEDY 10% 7H		

Keterangan: GEDY (Gel Ekstrak Daun Yodium)

Homogeneity test results obtained p value of 0.499 which means that the data is homogeneous ( $p > 0.05$ ). Therefore, the One Way

Anova test conditions can be met. The results of the One Way Anova test are as follows:

Table 4. One Way Anova test results

Group	Sel fibroblas	Sig	Desc
	<i>Mean ± SD</i>		
<i>Periodontal pack 5H</i>	44,00 ± 2,915	0,000	Different means
<i>Periodontal pack 7H</i>	63,20 ± 2,280		
GEDY 10% 5H	48,60 ± 1,817		
GEDY 10% 7H	69,40 ± 2,702		

Description: GEDY (Iodine Leaf Extract Gel)

Based on the results of the One Way Anova test, a p value of 0.000 ( $p < 0.05$ ) was obtained, which means that there was a significant difference in the average number of fibroblasts in each treatment group. To see the details of the comparison of each group, a follow-up test of One Way Anova was carried out,

namely the LSD Post Hoc Test with the results that there was a significant difference in the average number of fibroblasts at least between the 2 treatment groups. Furthermore, the LSD Post Hoc Test was carried out to determine the comparison in each treatment group. The results of the LSD Post Hoc Test are as follows:

Table 5. LSD . Post Hoc Test Results

	<b>Kelompok</b>	<b>Sig</b>	<b>Ket</b>
<i>Periodontal pack 5H</i>	<i>Periodontal pack 7H</i>	0,000	Different means
	GEDY 10% 5H	0,042	Different means
	GEDY 10% 7H	0,000	Different means
<i>Periodontal pack 7H</i>	GEDY 10% 5H	0,000	Different means
	GEDY 10% 7H	0,005	Different means
GEDY 10% 5H	GEDY 10% 7H	0,000	Different means

Description: GEDY (Iodine Leaf Extract Gel)

Based on the LSD Post Hoc Test results table, the comparison between each group obtained a p value <0.05, which means that there is a significant difference in the mean number of fibroblast cells in each treatment group.

## DISCUSSION

The study showed that the number of post-curettage fibroblasts in male wistar rats in each group, namely the 5th day periodontal pack was 35.20, the 7th day periodontal pack was 49.60, 10% iodine leaf extract gel (GEDY) plus periodontal the 5th day pack was 45.80, and 10% iodine leaf extract gel (GEDY) plus the 7th day periodontal pack was 50.80.

The administration of iodine leaf extract gel had a significant effect on the wound healing process after curettage. This is evidenced by the results of the One-Way Anova test which shows a p value > 0.05. Thus, 10% iodine leaf extract gel (*Jatropha multifida* L.) had an effect on post-curettage wound healing in male wistar rats seen from the number of fibroblast cells and in the periodontal pack group with the addition of iodine leaf extract gel on the 7th day which was the most effective compared to another group with an average number of fibroblast cells of 50.80.

In the treatment group, the mean number of fibroblasts was more than in the control group, which was given only the periodontal pack. The number of fibroblast cells in the control group was less because the periodontal pack only served to protect the wound from irritation, keep the wound area clean, control bleeding, and control excess tissue production. Periodontal pack does not contain ingredients that can accelerate wound healing<sup>9,10</sup>.

The flavonoid content in the iodine plant can inhibit cyclooxygenase or lipoxygenase and inhibit the accumulation of leukocytes in the wound area so that it can be anti-inflammatory. Flavonoids are able to inhibit nitric oxide production and inhibit iNOS expression, their anti-inflammatory power depends on the structure or subclass of flavonoids. In addition, flavonoids can also inhibit leukocyte accumulation in inflammatory areas<sup>11</sup>.

Flavonoids play a role in the wound healing process which can help accelerate wound healing by regulating cell function to stimulate the production of growth factors. The growth factor produced is TGF- $\beta$  (Transforming Growth Factor) which is able to increase the migration and proliferation of fibroblasts to the wound site<sup>12</sup>.

Saponins contained in iodine leaves can stimulate the formation of fibroblast cells which can accelerate wound healing. Saponins have an anti-inflammatory effect, when a wound occurs, it has the ability to stop bleeding by accelerating the precipitation and coagulation of red blood cells so as to accelerate wound healing.<sup>13</sup>

Tannins increase the tensile strength of the wound in the healing process. Tannins can cause skin pores to shrink (as an astringent) which stops light exudate and bleeding, thus preventing bleeding, closing wounds and accelerating epithelialization<sup>14</sup>. Thus, the content of flavonoids, saponins, and tannins in iodine plants affects the increase in the number of fibroblasts in post-curettage wound healing.

## CONCLUSION

The addition of plant extracts of iodine to the periodontal pack can increase the number of fibroblasts in post-curettage wound healing.

## BIBLIOGRAPHY

1. Caranza, F.A., Newman, M.G., Takei, H.H., Klokkevold, P.R. 2012. Carranza's *Clinical Periodontology*, 11th ed. Saunders Elsevier, China.
2. Dinyati M, Andi M.A. 2016. Kuretase Gingiva sebagai Perawatan Poket Periodontal. *Makassar Dent J*. Volume 5 Issue 2 Halaman 59.
3. Oktawati S, Lilies A.A. 2014. Perawatan Bedah Flap Periodontal pada Periodontitis Kronis: Sebuah Laporan Kasus. *Jurnal As-Syifaa*. Volume 06 (01) Halaman 98-106.
4. Baghani Z, Mahdi K. 2013. Periodontal Dressing: A Review Article. *J Dent Res Dent Clin Dent Prospect*. Volume 7 (4) Halaman 183-191.
5. Kathariya R, Hansa J, Tanya J. 2015. To Pack or Not to Pack: The Current Status of Periodontal Dressings. *J Appl Biomater Funct Mater*. Volume 13(2).
6. Sundaryono A, M. Lutfi F, Silvia F, Bhakti K. 2016. Potensi Ekstrak Daun Tanaman Betadin untuk Meningkatkan Jumlah Trombosit Penderita DBD Melalui Uji terhadap *Mus musculus*. *Prosiding Seminar Nasional Pendidikan Sains (SNPS)*. Halaman 403-410.
7. Fatriyadi J, Ika Y. 2016. Studi Pustaka Kemampuan Metabolit Sekunder Flavonoid dari Batang Jarak China (*Jatropha multifida L.*) dalam Meningkatkan Kadar Trombosit Penderita DHF. *Jurnal Majority*. Volume 5.
8. Dewi C. 2014. Perbedaan Efek Perawatan Luka dengan Menggunakan Getah Pohon Yodium Dibandingkan dengan Menggunakan *Povidon Iodine 10%* dalam Mempercepat Penyembuhan Luka Bersih pada Marmut (*Cavia porcellus*). *Jurnal Wiyata*. Volume (2).
9. Suryono. 2014. *Bedah Dasar Periodonsia*. Yogyakarta: Deepublish. Halaman 35-52
10. Pradita, A.U., Dhartono, A.P., Ramadhany, C.A., Taqwim, A. 2013. Periodontal Dressing-containing Green Tea *Epigallocatechin gallate* Increase Fibroblas Number in Gingival Artificial Wound Model. Original Article. Volume 20 (3) Halaman 68-72.
11. Ramadhani N, Sri A.S. 2016. Aktivitas Antiinflamasi Berbagai Tanaman Diduga Berasal Dari Flavonoid. *Jurnal Farmaka Suplemen*. Volume 14 (2).
12. Al-Fa'izah Z, Rahayu YC, Hikmah N. Peran Fibroblas pada Proses Penyembuhan Luka Pasca Pencabutan Gigi. *Digit Repos Univ Jember*. 2011;182-7.
13. Harisanraj, R., Suresh, K., dan Saravanababu, S. 2009. Evaluation of the Chemical Composition *Rauwolfia serpentina* and *Ephedra vulgaris*. *Advances on Biological Research*. Volume 3 (5-6) Halaman 174-178.
14. Putri R.R, Rachmi F.H, Sri R. 2017. Pengaruh Ekstrak Daun Tapak Dara (*Catharanthus roseus*) terhadap Jumlah Fibroblas pada Proses Penyembuhan Luka di Mukosa Oral. *Journal Caninus Denstistry*. Volume 2 (1) Halaman 20 – 30.