

ORAL MUCOSAL BURN CAUSED BY THE TOPICAL APPLICATION OF A CLOVE OIL CONCENTRATE

Sutrania Dewi Sulaksana*, Anandina Irmagita Soegyanto**

*Resident of Oral Medicine Residency Program Faculty of Dentistry, Universitas Indonesia

** Department of Oral Medicine, Faculty of Dentistry, Universitas Indonesia, Jakarta, Indonesia

Correspondence: anandina.irmagita74@ui.ac.id**Keywords:**

Apthous Stomatitis, Clove oil, Mucosal burn, Ulceration, Herbal medicine

ABSTRACT

Background: Clove is an herb that has been known for centuries as natural remedy and food preservatives. Despite its several important biological activities such as antioxidant activity, antimicrobial, antinociceptive, and antiviral effects, clove's end product can cause some tissue reaction that varies from low-grade local to serious reactions such as anaphylactic reaction. This case report aim to discuss on clove oil extract effect when applied topically to oral mucosal.

Case Presentation: A 30-year-old female came to Oral Medicine Clinic of Universitas Indonesia Dental Hospital, with complaint of painful multiple mouth ulceration since 3 weeks earlier that got worsen in the past 2 days after clove oil extract topical application. She had a history of canker sore in every 2 months since her adolescence. Extra oral examination showed desquamation and brown crust on lips. Intraoral examination revealed multiple, shallow, irregular ulcers, surrounded by diffuse erythema, on buccal mucosa, soft palate, anterior dorsum of the tongue, and lower anterior muco buccal fold. Subjective and clinical examination were consistent with oral mucosal burn and the patient was instructed to discontinue clove oil usage, while prescribed with Chlorhexidine Gluconate 0,2% mouthwash and Vaseline album.

Conclusion: The increasing practice of herbal medicine, such as cloves products, should raise our awareness since when used inappropriately, it could cause oral mucosal burn. In the management of these cases, dentist must perform thorough anamnesis and examination to establish accurate diagnosis and plan proper treatment.

INTRODUCTION

Clove (*Syzygium aromaticum*) is an herb which has been known for centuries and widely used for pharmaceutical, cosmetic, food and agricultural purposes.^{1,2} This plant is originally from Indonesia, however, it is also planted in some parts of the world such as India and Madagascar.² Due to its rich source of phenolic compounds, such as eugenol, clove has many important biological activities, like antioxidant, antimicrobial, antiviral, etc., which has been reported in several scientific

reports.^{2,3} Clove was also considered to have the ability as pain relief and to promote healing as herbal medicine topical application. It has two main components, eugenol (78%) and β -caryophyllene (13%).³ While in dentistry, eugenol derived from clove oil extract was known to be used as impression pastes, periodontal dressings, cements, endodontic sealers and as dressing for dry socket.^{4,5}

Despite its beneficial effects, some researches also mentioned various adverse effect

of clove, especially its cytotoxic effect when used inappropriately. Tissue reaction in consequence of the end products of clove / eugenol is varies from low-grade local reactions to systemic serious anaphylactic reactions. There are three type of tissue reaction that can be caused by clove adverse effect, which are direct tissue damage due to the nature of the medication; contact dermatitis or stomatitis and true allergic reaction.⁶

As the growing use of natural remedies in the community, the use of clove and its oil extract is commonly found. This case report will discuss the use of clove oil concentrate on recurrent aphtous stomatitis that had cause oral mucosal burn.

CASE PRESENTATION

A 30-year-old female patient came to Oral Medicine Clinic of Universitas Indonesia Dental Hospital, with a complaint of painful multiple ulceration of her oral cavity. First ulcer erupted around 3 weeks prior her visit, on her left tongue, which was accompanied with other ulcers on many areas of her mouth. Since there were many ulcers erupted that caused pain and discomfort, the patient tried to self-treat them with 100% clove oil extract which was applied using cotton bud, before she went to bed. The next morning, the patient felt burning sensation and more pain that interfere her ability to eat and swallow, so that she only can take soft diet. She revealed a history of recurrent oral ulcers every two months since her adolescence and also anaemia. The patient explained that her recurrent ulcers usually appear on tooth brushing irritation or trauma, and she rinses her mouth with salt solution daily. She also admitted the presence of psychological stress due to her work pressure for the past month.

Extra oral examination showed brown-crusted on both corner of the patient's mouth with dry and desquamated upper and lower lips. Lymph

nodes were non-palpable and non-tender. Intra oral examination revealed fair oral hygiene multiple irregular shallow ulcers in varied size, surrounded with diffuse erythematous area, on upper right buccal mucosa that extended to adjacent gingiva, right soft palate, anterior dorsum of the tongue, and muco buccal fold of 32 (Figure 1). The patient was instructed to fill in Depression, Anxiety, and Stress Scale (DASS-21) questionnaire to asses her psychological condition, which indicate the presence of severe anxiety and mild stress. Subjective and clinical examinations resulted a working diagnosis of Oral Mucosal Burn, due to the use of clove oil extract. The patient was instructed to discontinue the use of clove oil extract. She was prescribed chlorhexidine gluconate 0.2% mouthwash twice daily for a week to relieve her oral complain, and Vaseline album to improve her lip condition. In order to reduce patient's anxiety and stress, we also performed education on stress management. The patient was referred to perform complete blood count examination to rule out systemic disease of anaemia. Follow-up visit was planned in a week after her first one.

Due to patient's activity, the follow up visit was performed two weeks after the first visit. The patients admit that her previous painful oral ulcers had already healed within 3 days following the use of prescribed mouthwash. Nevertheless, she reported the presence of new ulcers after she changed her toothbrush. Patient also brought her complete blood count examination result which showed that all within normal limits. Clinical examination showed that all of the former ulcers already healed (Figure 2). A healed ulcer area was seen on the gingiva 21-22 and there was an oval shallow ulcer on the left soft palate area with the size of 0.5 x 1 cm. The patient was diagnosed with Recurrent Aphtous Stomatitis, prescribed with chlorhexidine gluconate 0.2% mouthwash to be

used twice daily and multivitamin to be taken once daily.

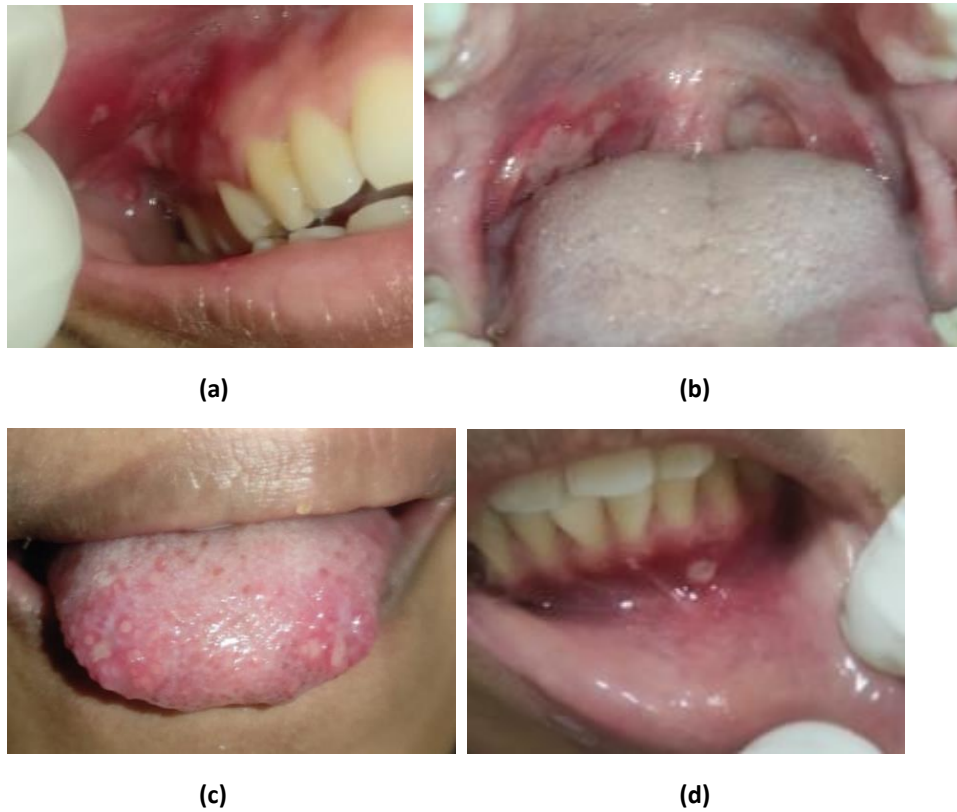

Figure 1. Shallow multiple irregular ulcer ranging from 0.5 to 3 cm in diameter with erythematous border, located on right buccal mucosa and gingiva (a), right soft palate (b), anterior dorsum of the tongue (c), muco buccal fold (d)

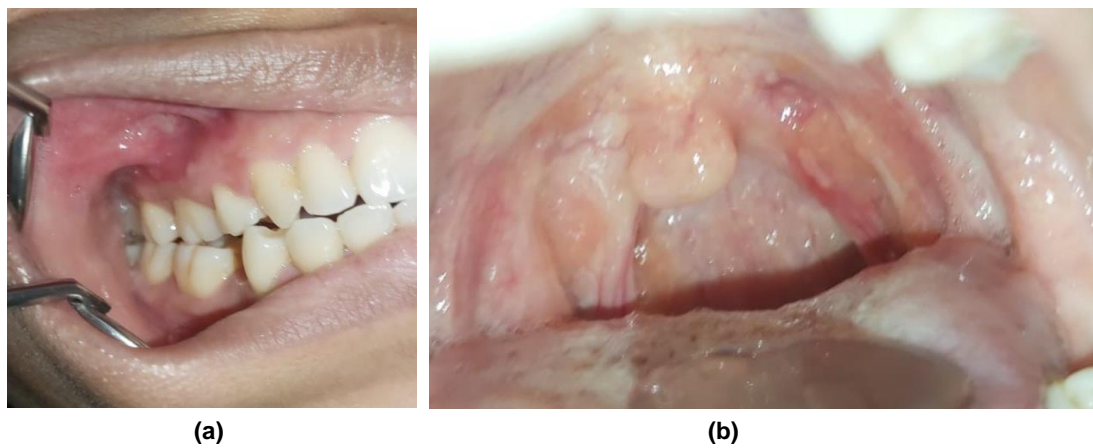

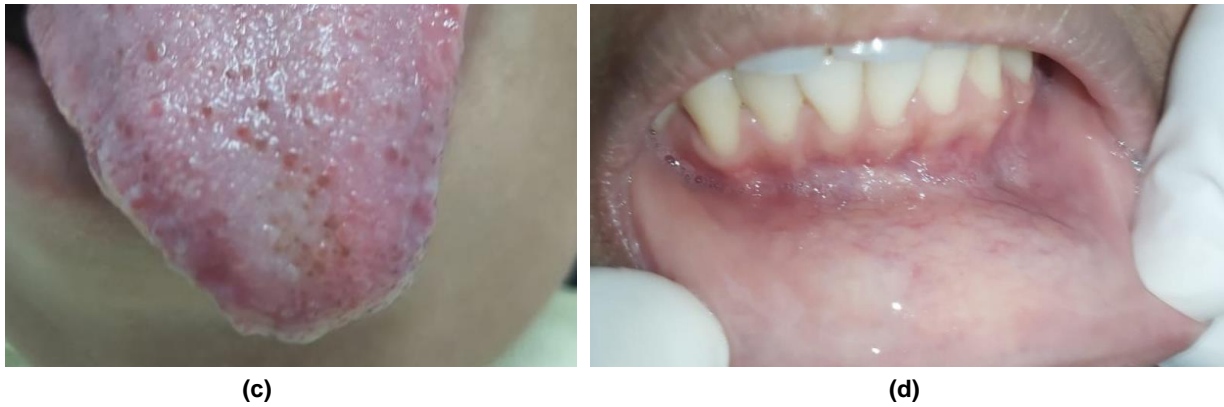


Figure 2. Healing of the ulcerated area ; right buccal mucosa and gingiva(a), soft palate and new ulcer aroused on left oropharynx(b), anterior dorsum of the tongue(c), muco buccal fold(d)

DISCUSSION

Oral Mucosal Burn is one of the most encountered lesion after the application of chemical agents that has caustic effect of the oral mucosa.^{7,8} Several chemical agent or medication commonly associated as the cause of chemical mucosal burn are aspirin, chlorpromazine, promazine, alendronate, tetracycline hydrochloride, recreational drug such as cocaine, 3,4-MDMA, some usual dental materials such as formocresol, sodium hypochlorite (NaOCl), eugenol, hydrogen peroxide ; and non-pharmaceutical substances such as garlic, clove or mint.^{4,5,9} In our case, the presence of oral mucosal burn was diagnosed based on clinical feature of the lesion and the history of Clove Oil Extract application. Histopathological examination of lesional and perilesional tissue is seldom indicated except it is difficult to determine an adequate history or if there is a suspicious to malignancy lesions.⁷

Chemical agents causing mucosal burn by varies mechanism acting via direct damage on their acidic or alkaline nature. Organic and inorganic acids conduct to bind with epithelium (tissue) protein and damage the cell's protein, then guide to coagulative necrosis of the cells. The protein and collagen was destroyed by alkalis, continue to

hydrolysis reaction of fatty tissue and liquefactive necrosis.⁷ Clinical features may establish as immediate erythema and oedema of the oral mucosa and gingiva, following exposure of the caustic agent. Later formation generally of white slough pseudo membrane covering the underlying ulceration. Chemical burn can affect any site of oral mucosal, but ulcer extension depends on the agent involved.^{10,11,12} Mild chemical injury heals on their own once the irritant is removed. Communication, information and education of caustic substances is important to avoid the re-injury.^{13,14}

The prescription of Chlorhexidine Gluconate mouthwash was considered as a line therapy based on its strong anti-inflammatory effect by reducing the basal concentration of leucocytes migrating into the lesion. It is also reduced the levels of the pro-inflammatory cytokines, that would be beneficial in relieving patient's discomforts.^{15,16}

There are many herbal medicine online trading in Indonesia, that claim as "alternative" medication for so many diseases, including to treat ulceration in the oral cavity that contain clove oil concentrate.¹⁷ Herbal medicine is still popular in the 75 to 80% world's population and mainly in the developing

countries.^{1,17} They believe herbal drugs are without any side effects, moreover of its cost-effectiveness and availability.^{17,18,19} In this case, patient self-inflicted therapeutic error due to patient's improper use by directly applied 100% Clove Oil Extract to all of the ulcers without being diluted. The Food and Drug Administration has recognized it as non-carcinogenic and non-mutagenic component, but some researches show cytotoxic agents of both the oil and eugenol, against human fibroblasts and endothelial cells.^{3,4}

CONCLUSION

The increasing practice of herbal medicine, such as cloves products, should raise our awareness since when used inappropriately, it could cause oral mucosal burn. In the management of these cases, dentist must perform thorough anamnesis and examination to establish accurate diagnosis and plan proper treatment.

REFERENCES

- Batiha GES, Alkazmi LM, Wasef LG, Beshbishy AM, Nadwa EH, Rashwan EK. *Syzygium aromaticum* L. (myrtaceae): Traditional uses, bioactive chemical constituents, pharmacological and toxicological activities. *Biomolecules*. 2020;10(2). doi:10.3390/biom10020202
- Cortés-Rojas DF, de Souza CRF, Oliveira WP. Clove (*Syzygium aromaticum*): A precious spice. *Asian Pac J Trop Biomed*. 2014;4(2):90-96. doi:10.1016/S2221-1691(14)60215-X
- Prashar A, Locke IC, Evans CS. Cytotoxicity of clove (*Syzygium aromaticum*) oil and its major components to human skin cells. *Cell Prolif*. 2006;39(4):241-248. doi:10.1111/j.1365-2184.2006.00384.x
- Deshpande A, Verma S, Macwan C. Allergic Reaction Associated with the use of Eugenol Containing Dental Cement in a Young Child. *Austin J Dent*. 2014;1(2):1-3.
- Sarrami N, Pemberton MN, Thornhill MH, Theaker ED. Adverse reactions associated with the use of eugenol in dentistry. *Br Dent J*. 2002;193(5):257-259. doi:10.1038/sj.bdj.4801539
- Barboza JN, da Silva Maia Bezerra Filho C, Silva RO, Medeiros JVR, de Sousa DP. An overview on the anti-inflammatory potential and antioxidant profile of eugenol. *Oxid Med Cell Longev*. 2018;2018. doi:10.1155/2018/3957262
- Gilvetti C, Porter SR, Fedele S. Traumatic chemical oral ulceration: A case report and review of the literature. *Br Dent J*. 2010;208(7):297-300. doi:10.1038/sj.bdj.2010.295
- Meltem Koray, Tosun Tosun. Chemical injuries of the oral mucosa. In: Serdar Gozler, ed. *Trauma in Dentistry*. IntechOpen; 2019. doi:10.5772/intechopen.77126
- Dayakar MM, Pai PG, Sooranagi RP, Vijayan V WA. Chemical burns of gingiva and its management. *SRM J Res Dent Sci*. 2018;9(80):174. doi:10.4103/srmjrd.srmjrds
- Glick M. *Burket's Oral Medicine*. 12th ed. People's Medical Publishing House; 2015.
- Naganawa T, Murozumi H, Kumar A, Okuyama A, Okamoto T, Ando T. Intraoral chemical burn in an elderly patient with dementia. *Int J Burns Trauma*. 2015;5(3):79-81. <http://www.ncbi.nlm.nih.gov/pubmed/26550533> <http://www.pubmedcentral.nih.gov/articlerender.fcgi?artid=PMC4620123>
- Girish M, Anandakrishna L, Chandra P, Nandlal B, Srilatha K. Iatrogenic injury of oral mucosa due to Chemicals: A Case report of formocresol injury and review. *IOSR J Dent Med Sci Ver IX*. 2015;14(4):2279-2861. doi:10.9790/0853-14490105
- Tammannavar P, Pushpalatha C, Jain S, Sowmya S V. An unexpected positive hypersensitive reaction to eugenol. *BMJ Case Rep*. Published online 2013:2-5. doi:10.1136/bcr-2013-009464
- Ramalingam K, Abdalla KA. Traumatic Chemical Oral Ulceration – Aspirin Burn – a Case Report From Libya. *CIBTech J Surg*. 2016;5(2):2319-3875.
- Halabi A, Wa S. Inflammatory response to chlorhexidine, minocycline HCl and doxycycline HCl in an in vivo mouse model. Published online 2008:783-788. doi:10.1111/j.1600-051X.2008.01290.x
- Natalie Rose Edgar, Dahlia Saleh RAM. Recurrent Aphtous Stomatitis : A Review. *J Clin Aesthet Dermatol*. 2017;10(8.5.2017):26-36.
- Pal SK, Shukla Y. Herbal medicine: Current status and the future. *Asian Pacific J Cancer Prev*. 2003;4(4):281-288.
- Mohammadi Nejad S, Özgüneş H, Başaran

- N. Pharmacological and Toxicological Properties of Eugenol. *Turkish J Pharm Sci.* 2017;14(2):201-206. doi:10.4274/tjps.62207
19. Kamatou GP, Vermaak I, Viljoen AM. Eugenol - From the remote Maluku Islands to the international market place: A review of a remarkable and versatile molecule. *Molecules.* 2012;17(6):6953-6981. doi:10.3390/molecules17066953