

## Characteristics of Mandibular Oral Squamous Cell Carcinoma at Hasan Sadikin General Hospital Bandung Oral and Maxillofacial Surgery Department on January 2017 – 2023

Khtriztie Limanthara\*, Harmas Yazid\*\*, Asri Arumsari\*\*\*, Dian Maifara\*\*

\* Oral and maxillofacial surgery resident, Faculty of Dentistry, Department Oral and Maxillofacial Surgery, Universitas Padjajaran, Bandung, Indonesia

\*\* Staff of the Oral and Maxillofacial Surgery Department, Faculty of Dentistry, Department Oral and Maxillofacial Surgery, Universitas Padjajaran, Bandung, Indonesia

\*\*\* Staff of the Oral and Maxillofacial Surgery Department, Hasan Sadikin General Hospital, Bandung, Indonesia.

Correspondence: [thiliem7@gmail.com](mailto:thiliem7@gmail.com)

Received 24 November 2023; 1<sup>st</sup> revision 18 March 2024; 2<sup>nd</sup> revision 5 July 2024; Accepted 12 July 2024; Published online 31 July 2024

### Keywords:

Squamous-cell carcinoma, mandible, characteristics

### ABSTRACT

**Background:** Oral cancer is a highly prevalent cancer with a high incidence rate around the globe. Oral squamous cell carcinoma accounts for 90–95% of cases of oral cancer. With a tendency to spread rapidly, it primarily affects the palate, mandible, lower lip, tongue, and floor of the mouth. The elevated frequency of occurrences emphasizes the necessity for a study to investigate the attributes of mandibular squamous cell carcinoma, particularly within the Oral and Maxillofacial Surgery Department at Hasan Sadikin General Hospital in Bandung.

**Methods:** This study adopts a retrospective descriptive approach, utilizing secondary data from medical records from 45 patients diagnosed with mandible squamous cell carcinoma from January 2017 to 2023, based on histopathological examination results.

**Results:** Over 48-year-olds are the most common age group affected by mandible squamous cell carcinoma, accounting for 69% of cases. Males account for 51% of cases. Bandung, West Java, has the highest incidence, with 16 cases. Treatment mainly consists of surgery and chemotherapy/radiotherapy, with the mandibular corpus being the most frequent site, affecting 84% of cases.

**Conclusion:** There were 45 patients diagnosed with mandibular squamous cell carcinoma at Hasan Sadikin General Hospital in Bandung between January 2017 - 2023. The data was analyzed based on the age, gender, domicile, therapy, and specific location within the mandible in order to determine the distribution of these cases.

Copyright ©2024 National Research and Innovation Agency. This is an open access article under the CC BY-SA license (<https://creativecommons.org/licenses/by-sa/4.0/>).

doi: <http://dx.doi.org/10.30659/odj.11.1.30-38>

2460-4119 / 2354-5992 ©2024 National Research and Innovation Agency

This is an open access article under the CC BY-SA license (<https://creativecommons.org/licenses/by-sa/4.0/>)

Odonto : Dental Journal accredited as Sinta 2 Journal (<https://sinta.kemdikbud.go.id/journals/profile/3200>)

How to Cite: *Limanthara et al.* Characteristics of Mandibular Oral Squamous Cell Carcinoma at Hasan Sadikin General Hospital Bandung Oral and Maxillofacial Surgery Department on January 2017 – 2023. *Odonto: Dental Journal*, v.11, n.1, p.30-38, July 2024.

## INTRODUCTION

Oral cancer is one of the ten most prevalent and high-incidence malignancies worldwide, posing a challenge for oral and maxillofacial surgeons in its management.<sup>1</sup> Oral squamous cell carcinoma (OSCC) is the most prevalent oral malignancy, contributing to approximately 90-95% of cases of all oral cancer. Oral squamous cell carcinoma is a malignant neoplasm that develops from the mucosal epithelium of the mouth cavity and exhibits varied squamous differentiation. This neoplasm is the second most common type of non-melanoma neoplasm after basal cell carcinoma.<sup>2</sup>

According to the World Health Organization (WHO), the global incidence of OSCC is estimated to be 377,713 cases with a death rate of 177,757 in 2020. In developing countries, the mortality rate for head and neck cancer exceeds 70%, with 30% of patients recovering after therapy.<sup>3</sup> This data is in line with data from the International Agency for Research on Cancer (IARC) in 2018 which showed that there were 354,864 new cases of oral cancer accompanied by 177,384 deaths due to oral cancer worldwide.<sup>4</sup> According to the data presented above, OSCC is one of the leading causes of cancer-related deaths worldwide.

Oral squamous cell carcinoma often occurs on the lower lip, the floor of the mouth, tongue, mandible, and palate with a tendency to rapidly metastasize. The presence of lymph node (LN) metastases is the most important prognostic factor in oral squamous cell carcinomas (OSCC), as it reduces the survival rate by nearly 50%. Major etiological factors for OSCC including human papillomavirus (HPV) and bad habits such as smoking, betel nuts, and alcohol.<sup>5</sup> In general, oral cancer patients have a poor prognosis. When the mandibular region involved, the survival rate is the lowest of the whole oral cavity.<sup>6</sup> Management of squamous cell carcinoma includes surgery, radiation, chemotherapy, or a combination of both. Definitive therapy including total glossectomy, hemiglossectomy, and wide excision with reconstruction. Radiotherapy and chemotherapy can be used as neo-adjuvant therapy, depending on the size of the lesion, location of the lesion, and metastases that have occurred.<sup>7</sup>

Research on the characteristics of OSCC at Hasan Sadikin General Hospital, Bandung from January to December 2019 showed an incidence of 28 cases. The most common location is on the tongue and occurs more often in women aged 18-65 years. In this study, the majority of patients with OSCC had undergone definitive therapy.<sup>8</sup> The high prevalence of oral squamous cell carcinoma emphasizes the necessity for a study to investigate the attributes of mandibular squamous cell carcinoma, particularly within the Oral and Maxillofacial Surgery Department at Hasan Sadikin General Hospital in Bandung. Based on previous research, researchers are interested in examining the characteristics of Oral squamous cell carcinoma in the mandible, especially at Hasan Sadikin General Hospital, Bandung Oral and Maxillofacial Surgery Department.

## METHODS

This research is a retrospective descriptive study using secondary data sources, which is medical record data of patients who have been diagnosed with OSCC of the mandible at the Hasan Sadikin General Hospital, Bandung Oral and Maxillofacial Surgery Department, on January 2017 to January 2023 based on histopathological examination. This research has an ethical approval letter Hasan Sadikin General Hospital, Bandung.

In this study, the subjects were all patients with a diagnosis of oral squamous cell carcinoma of the mandible at the Hasan Sadikin General Hospital, Bandung Oral and Maxillofacial Surgery Department from January 2017 to January 2023 which met the inclusion and exclusion criteria. The inclusion criteria in this study were: (1) Patients with OSCC of the mandible who had undergone histopathological examination, (2) Patients with OSCC of the mandible at Hasan Sadikin General Hospital, Bandung Oral and Maxillofacial Surgery Department from January 2017 to January 2023. The exclusion criteria in this study were: (1) Patients who were diagnosed with OSCC with the results of a histopathological examination from outside Hasan Sadikin General Hospital, Bandung.

The variables in this study were age, gender, domicile, and anatomical pathology examination results consisting of poorly differentiated, moderately differentiated, and well differentiated. The therapy of OSCC in this study was surgery, radiation, chemotherapy, and combinations. The locations of OSCC in this study were in the symphysis, para symphysis, corpus, angulus, ramus, and condyle of the mandible. Age was defined as age at diagnosis. Gender is defined as the sex at birth. Domicile is defined as a person's residence. Therapy is defined as the therapeutic options provided to patients. Location was defined as a site involving squamous cell carcinoma. The sampling process was carried out using the purposive sampling method. Secondary data originating from medical records is analysed then sorted and presented in the form of tables and percentages.

## RESULTS

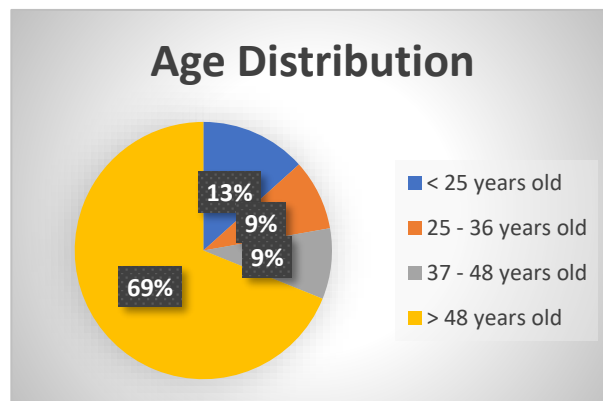
This research was carried out at the Hasan Sadikin General Hospital, Bandung Oral and Maxillofacial Surgery Department from January 2017 to January 2023. The data obtained was 45 cases. The sample was obtained from secondary data through medical records of patients with squamous cell carcinoma of the mandible at Hasan Sadikin General Hospital, Bandung Oral and Maxillofacial Surgery Department for the period of January 2017 to January 2023 to determine the prevalence based on age, gender, domicile, therapy, and location in the mandible. The results of this research will be described in table 1.

**Table 1.** Characteristics of research subjects

Characteristic	Frequency (n=45)	Percentage (%)
<b>Age (year)</b>		
< 25	6	13
25–36	4	9
37–48	4	9
>48	31	69
<b>Gender</b>		
Male	23	51
Female	22	49
<b>Domicile</b>		
West Java	41	96
Outside West Java	4	4

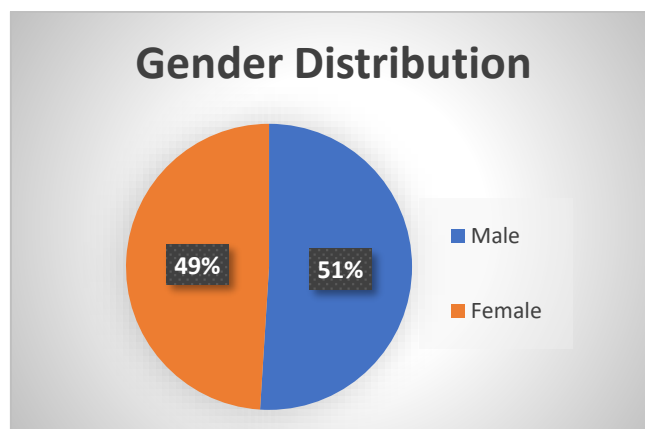
<b>Therapy</b>		
Surgery	10	22
Radiation	8	18
Chemotherapy	10	22
Combination	17	38
<b>Location in Mandible</b>		
Symphysis	5	11
Parasymphysis	2	5
Corpus	38	84
Angulus	0	0
Ramus	0	0
Condyle	0	0

Based on data from medical records, it showed that the number of data in the age group under 25 years is 6 people (13%), the 25-36 year age group is 4 peoples (9%), the 37-48 age group is 4 people (9%), and the age group over 48 years was 31 people (69%).



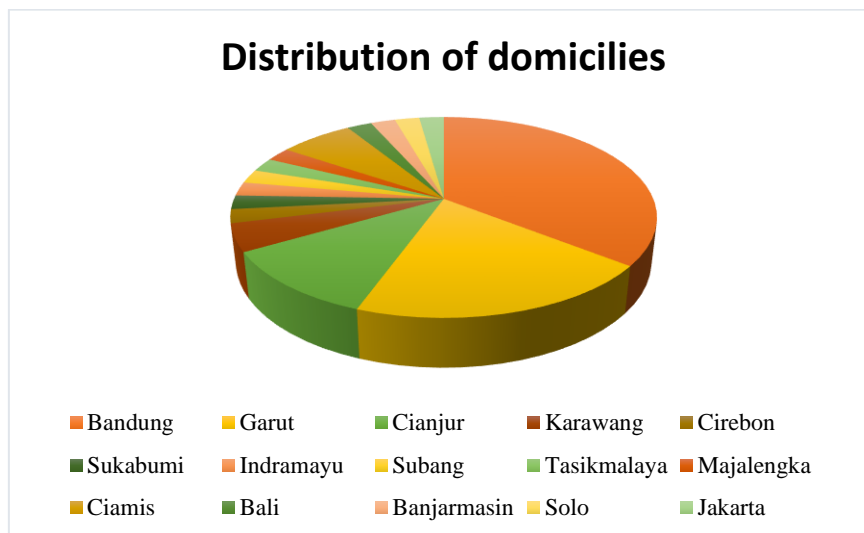
**Figure 1.** Age distribution of patients diagnosed with squamous cell carcinoma of the mandible at the Oral and Maxillofacial Surgery Department, Hasan Sadikin General Hospital, Bandung period from January 2017 to January 2023

Based on gender criteria, it showed that the number of patients is 23 male (51%) and 22 female (49%).



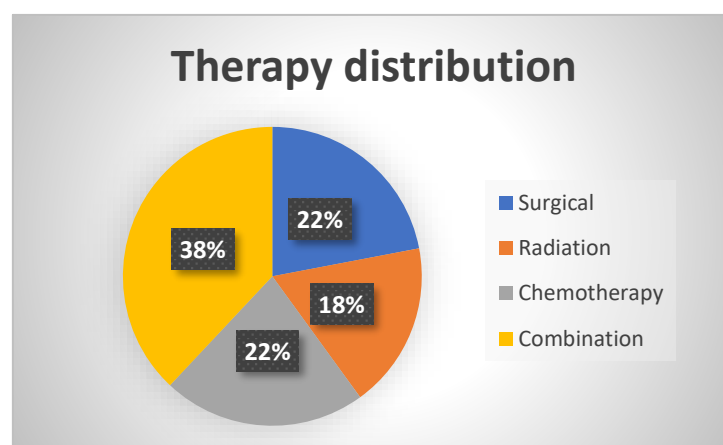
**Figure 2.** Gender distribution of patients diagnosed with squamous cell carcinoma of the mandible at the Oral and Maxillofacial Surgery Department, Hasan Sadikin General Hospital, Bandung period from January 2017 to January 2023

Based on domicile, it showed that the 3 highest domiciles of patients with squamous cell carcinoma of the mandible are in Bandung City with 16 people (36%), Garut with 9 people (20%), Cianjur with 5 people (11%).



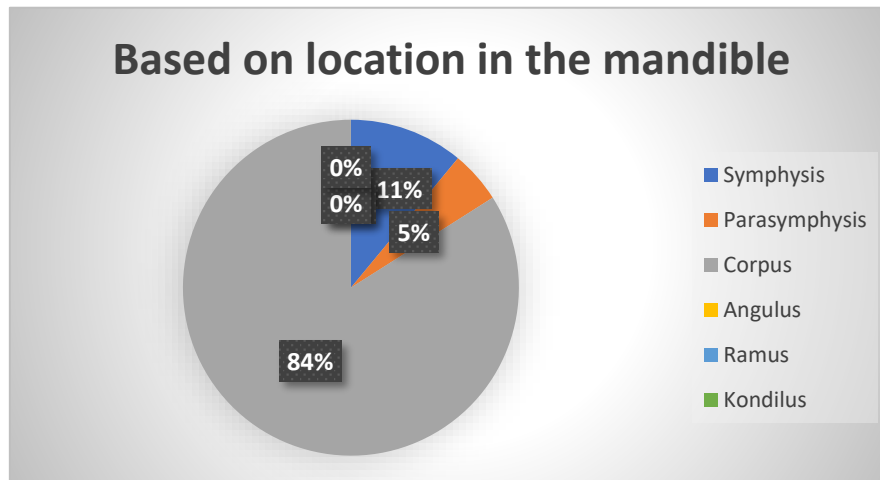
**Figure 3.** Distribution of domiciles of patients diagnosed with squamous cell carcinoma of the mandible at the Oral and Maxillofacial Surgery Department, Hasan Sadikin General Hospital, Bandung period from January 2017 to January 2023

Based on the therapy carried out, it showed that 10 people (22%) chose chemotherapy therapy, 8 people (18%) had radiotherapy, 10 people (22%) had surgery, and 17 people (38%) combined surgery and radiotherapy/chemotherapy.



**Figure 4.** Distribution of therapy for patients diagnosed with squamous cell carcinoma of the mandible at the Oral and Maxillofacial Surgery Department, Hasan Sadikin General Hospital, Bandung for the period from January 2017 to January 2023

Based on location in the mandible, it showed that the highest incidence of squamous cell carcinoma occurring in the mandibular corpus was 38 people (84%), the mandibular symphysis was 5 people (11%), the para symphysis was 2 people (5%), which can be seen from Table 4.5.



**Figure 5.** Distribution of patients based on location in the mandible with a diagnosis of squamous cell carcinoma of the mandible at the Oral and Maxillofacial Surgery Department, Hasan Sadikin General Hospital, Bandung, Bandung for the period from January 2017 to January 2023

## DISCUSSION

OSCC is the most frequent form of head and neck cancer. Based on previous research, OSCC can occur in all parts of the oral cavity, including the tongue, the floor of the mouth, palate, buccal mucosa, and also the gingiva of both the maxilla and mandible.<sup>13</sup> In this study, there were 45 cases of squamous cell carcinoma in the mandible over 6 years. This result showed that the incidence of OSCC in the mandible is also quite high, compared to other locations in the oral cavity. The prevalence of squamous cell carcinoma in the mandible based on gender showed that males (51%) are higher than females (49%), this is in line with research conducted by Thomson et al in Hong Kong.<sup>12</sup> This study found that patients in the age category over 48 years were the age category with the highest incidence, namely 31 people (69%), this is also in line with research by Thomson et al.<sup>12</sup> The majority of patients in this study came from West Java, which is the city of Bandung.

Oral squamous cell carcinoma is an oral cancer with a high mortality rate. Early stages of oral squamous cell carcinoma are typically asymptomatic and often ignored by patients, leading to late detection.<sup>27</sup> Patients often present to the hospital at an advanced stage. Paraneoplastic syndrome can be caused by cancer growth in the mouth cavity or metastasis to other organs, resulting in mortality.<sup>8</sup> Oral squamous cell carcinoma that affects the mandible has the lowest survival rate and hence has the worst prognosis due to the highest rate of recurrence.<sup>6</sup> The etiology of squamous cell carcinoma is multifactorial and requires a complex process.<sup>28</sup> The risk factors of OSCC are candida infections, nutritional deficiencies, chronic irritation, excessive use of mouthwash, and consumption of tobacco, alcoholic drinks, and betel. These risk factors can play a role individually or in combination in the process of developing this cancer.<sup>1,29</sup> HSV and HPV are considered to play a very important role in developing OSCC. Genetic mutations in DNA are also one of the factors causing this cancer. Activation of protooncogenes (RAS proteins, myc gene, Epidermal Growth Factor Receptor (EGFR) gene) or inhibition of tumor suppressor genes (tumor protein TP53, retinoblastoma protein (pRb), p16 protein) by environmental factors can increase the risk of oral squamous cell carcinoma.<sup>13</sup> This genetic mutation causes

hyperplasia, cellular dysplasia, irregular cell growth, and eventually carcinoma. Research suggests that alcohol and tobacco use are risk factors for 75% of oral malignancies, making prevention a priority. For the 25% of individuals who were not exposed to these substances, the exact cause of their tumors remains unknown.<sup>28</sup>

Based on the result of this study, the most common location for squamous cell carcinoma in the mandible in the corpus of the mandible, most of which is managed in a multidisciplinary manner, namely a combination of surgery as well as radiotherapy and chemotherapy. Multidisciplinary management in several studies regarding cancer of the oral cavity showed that this treatment can increase the survival rate of patients with oral squamous cell carcinoma.<sup>30</sup>

## CONCLUSION

Results of data collection on the characteristics of mandibular squamous cell carcinoma at Dr. Hasan Sadikin Central General Hospital as follows: The age group over 48 years was more likely to be affected by squamous cell carcinoma of the mandible with a total of 31 people (69% of cases). The majority of patients suffering from squamous cell carcinoma of the mandible are male, which was 23 people (51%). Bandung is a city in West Java with the highest cases of mandibular squamous cell carcinoma with 16 people (36% of cases). Most patients with mandibular squamous cell carcinoma were treated with a combination of surgery and chemotherapy/radiotherapy, namely 17 people (38% of cases). The most common location of mandibular squamous cell carcinoma was in the mandibular corpus, namely 38 people (84% of cases). With the high incidence of OSCC, dentists play an important part in recognizing OSCC. Early diagnosis and multidisciplinary management of OSCC, along with proper treatment, can improve patient outcomes and their quality of life. Avoiding preventable risk factors such as smoking, alcohol intake, and betel nut chewing may contribute to lowering the occurrence of OSCC.

## REFERENCES

1. Rivera C. Essentials of oral cancer. *Int J Clin Exp Pathol*. 2015 Sep 1;8(9):11884–94.
2. Gunawan G, Firman RN, Pramanik F, Nurrachman AS. Gambaran squamous cell carcinoma posterior mandibula pada radiograf panoramik. *JRDI*. 2020 May 10;4(1):41.
3. Miranda-Filho A, Bray F. Global patterns and trends in cancers of the lip, tongue and mouth. *Oral Oncology*. 2020 Mar 1;102:104551.
4. Global cancer statistics 2018: GLOBOCAN estimates of incidence and mortality worldwide for 36 cancers in 185 countries - PubMed [Internet]. [cited 2023 Mar 16]. Available from: <https://pubmed.ncbi.nlm.nih.gov/30207593>
5. Pranata N. Deteksi Dini Oral Squamous Sel Carcinoma (OSCC) dengan Menggunakan Human Papillomavirus (HPV) sebagai Penandanya. *SONDE (Sound of Dentistry)*. 2018;3(2):108–17.
6. Givony S. Oral squamous cell carcinoma (OSCC) an overview. 2020;8(13).
7. De Vicente, J. C., Recio, O. R., Pendás, S. L., & López-Arranz, J. S. (2001). Oral squamous cell carcinoma of the mandibular region: A survival study. *Head & Neck*, 23(7), 536–543. doi:10.1002/hed.1075
8. Setoaji I, Priyanto W, Hardianto A. Karakteristik Karsinoma Sel Skuamosa Rongga Mulut di RSUP Dr. Hasan Sadikin Bandung. *Jurnal Kedokteran dan Kesehatan: Publikasi Ilmiah Fakultas Kedokteran Universitas Sriwijaya*. 2022 Jan 1;9(1):97–102.
9. Tandon P, Dadhich A, Saluja H, Bawane S, Sachdeva S. The prevalence of squamous cell carcinoma in different sites of oral cavity at our Rural Health Care Centre in Loni, Maharashtra - a retrospective 10-year study. *Contemp Oncol (Pozn)*. 2017;21(2):178–83.
10. Joshi P, Dutta S, Chaturvedi P, Nair S. Head and neck cancers in developing countries. *Rambam Maimonides Med J*. 2014 Apr;5(2):e0009.

11. Bugshan A, Farooq I. Oral squamous cell carcinoma: metastasis, potentially associated malignant disorders, etiology and recent advancements in diagnosis. *F1000Res*. 2020 Apr 2;9:229.
12. Thomson PJ. Perspectives on oral squamous cell carcinoma prevention-proliferation, position, progression and prediction. *J Oral Pathol Med*. 2018 Oct;47(9):803–7.
13. Neville BW, Damm DD, Allen CM, Chi AC. *Oral and maxillofacial pathology*. Elsevier Health Sciences; 2015.
14. Chen SH, Hsiao SY, Chang KY, Chang JY. New Insights Into Oral Squamous Cell Carcinoma: From Clinical Aspects to Molecular Tumorigenesis. *Int J Mol Sci*. 2021 Feb 24;22(5):2252.
15. *Oral Squamous Cell Carcinoma: From Diagnosis to Treatment – Nova Science Publishers [Internet]*. [cited 2023 Mar 24]. Available from: <https://novapublishers.com/shop/oral-squamous-cell-carcinoma-from-diagnosis-to-treatment/>
16. Faria S de O, Nascimento MC do, Kulcsar MAV. Malignant neoplasms of the oral cavity and oropharynx treated in Brazil: what do hospital cancer records reveal? *Braz J Otorhinolaryngol*. 2020 Jun 24;88(2):168–73.
17. Kusuma ARP. Pengaruh Merokok Terhadap Kesehatan Gigi Dan Rongga Mulut. *Majalah Ilmiah Sultan Agung*. 2023 Mar 27;49(124):12–9.
18. Tenore G, Nuvoli A, Mohsen A, Cassoni A, Battisti A, Terenzi V, et al. Tobacco, Alcohol and Family History of Cancer as Risk Factors of Oral Squamous Cell Carcinoma: Case-Control Retrospective Study. *Applied Sciences*. 2020 Jan;10(11):3896.
19. Fardizza F, Hermani B, Tamin S. The role of human papillomavirus in advanced laryngeal squamous cell carcinoma. *Oto Rhino Laryngologica Indonesiana*. 2016 Dec 30;46(2):155–64.
20. *Head and Neck Pathology - 3rd Edition [Internet]*. [cited 2023 Mar 27]. Available from: <https://www.elsevier.com/books/head-and-neck-pathology/thompson/978-0-323-47916-5>
21. Wetzel SL, Wollenberg J. Oral Potentially Malignant Disorders. *Dent Clin North Am*. 2020 Jan;64(1):25–37.
22. Chi AC, Day TA, Neville BW. Oral cavity and oropharyngeal squamous cell carcinoma—an update. *CA: A Cancer Journal for Clinicians*. 2015;65(5):401–21.
23. Mneimneh WS, Xu B, Ghossein C, Alzumaili B, Sethi S, Ganly I, et al. Clinicopathologic Characteristics of Young Patients with Oral Squamous Cell Carcinoma. *Head Neck Pathol*. 2021 Apr 2;15(4):1099–108.
24. Chhabra N, Chhabra S, Sapra N. Diagnostic Modalities for Squamous Cell Carcinoma: An Extensive Review of Literature-Considering Toluidine Blue as a Useful Adjunct. *J Maxillofac Oral Surg*. 2015 Jun;14(2):188–200.
25. Omar EA. The Outline of Prognosis and New Advances in Diagnosis of Oral Squamous Cell Carcinoma (OSCC): Review of the Literature. In: *Journal of Oral Oncology [Internet]*. 2013 [cited 2023 Mar 28]. p. 1–13. Available from: <https://www.hindawi.com/journals/joo/2013/519312/>
26. Abhyankar V, Ferrence S, Shokoufeh Shahrabi-Farahani, Jules Mascerenhas, Paul Luepke, K Mark Anderson. *Biopsy Technique and Histopathological Diagnosis of Oral*. 2020;
27. Harmiyati, R., Sufiawati, I., Nugraha, H.G. 2022. The Role of Magnetic Resonance Imaging in The Diagnosis and Staging of Oral Squamous Cell Carcinoma. *Odonto Dental Journal*. Vol 9. Special Issue 1.
28. Mehrota, R., Yadav S. Oral squamous cell carcinoma: Etiology, pathogenesis and prognostic value of genomic alterations. *Indian Journal of Cancer*. April-June 2006. 43(2)
29. Pałasz P, Adamski Ł, Górska-Chrząstek M, Starzyńska A, Studniarek M. Contemporary Diagnostic Imaging of Oral Squamous Cell Carcinoma – A Review of Literature. *Polish Journal of Radiology*. 2018;82:193–202.
30. Mroueh R, Haapaniemi A, Grénman R, Laranne J, Pukkila M, Almangush A, et al. Improved outcomes with oral tongue squamous cell carcinoma in Finland. *Head Neck*. 2017 Jul;39(7):1306–12.